

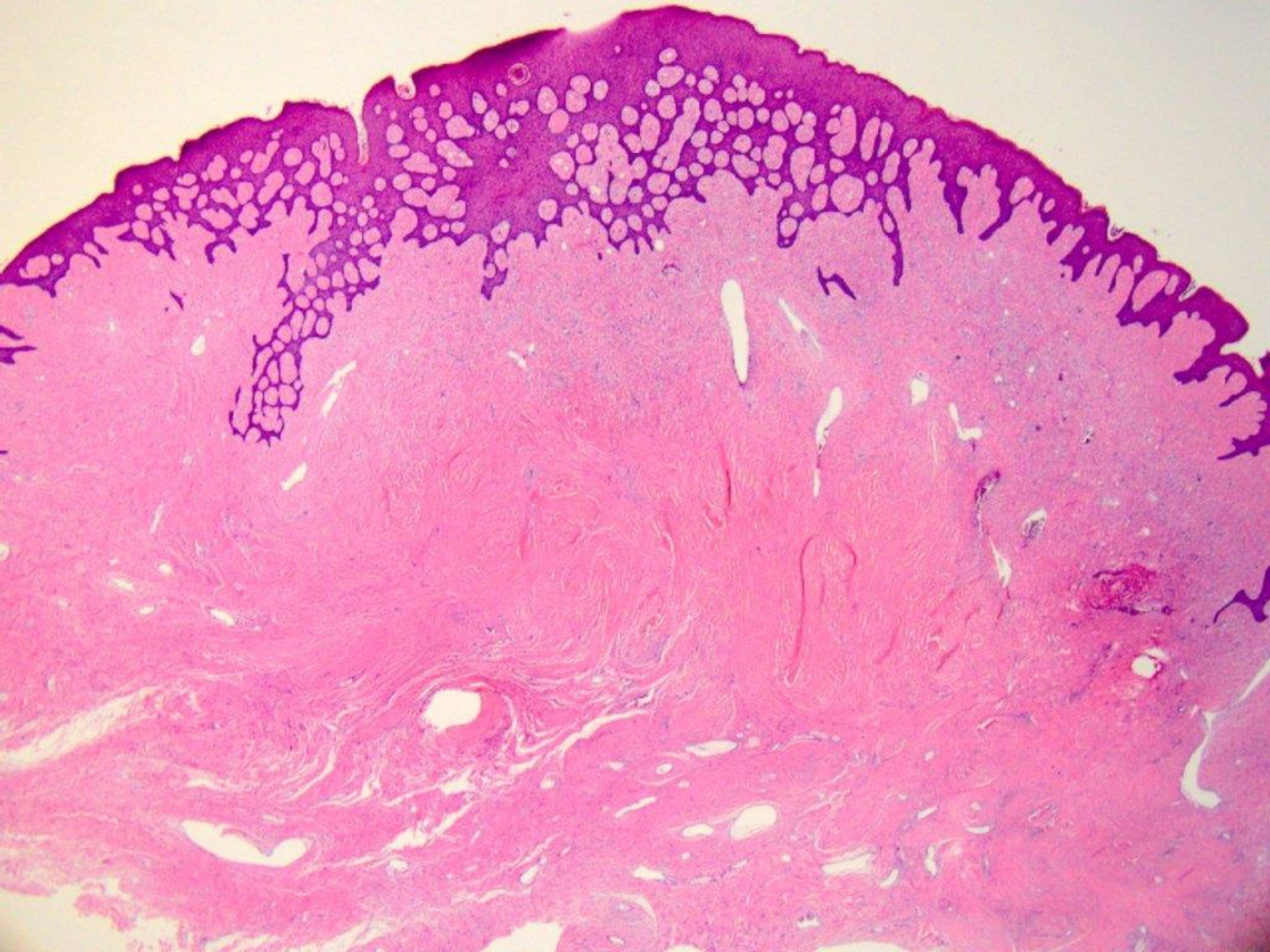
# Oral Histopathology

## Series 31

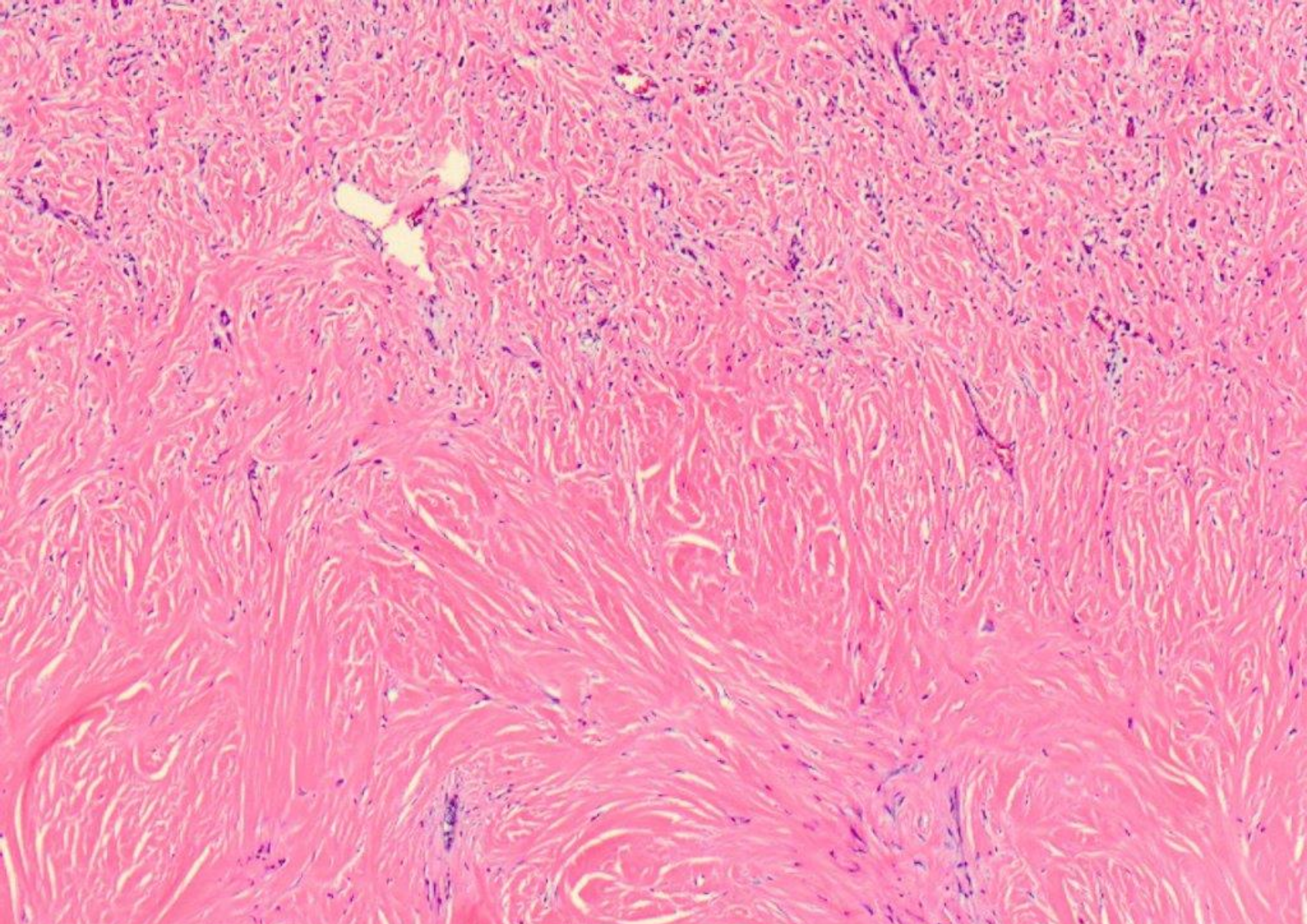
**DAVID E. KLINGMAN, DMD**

*Diplomate, American Board of Oral and Maxillofacial Pathology*

*Diplomate, American Board of General Dentistry*

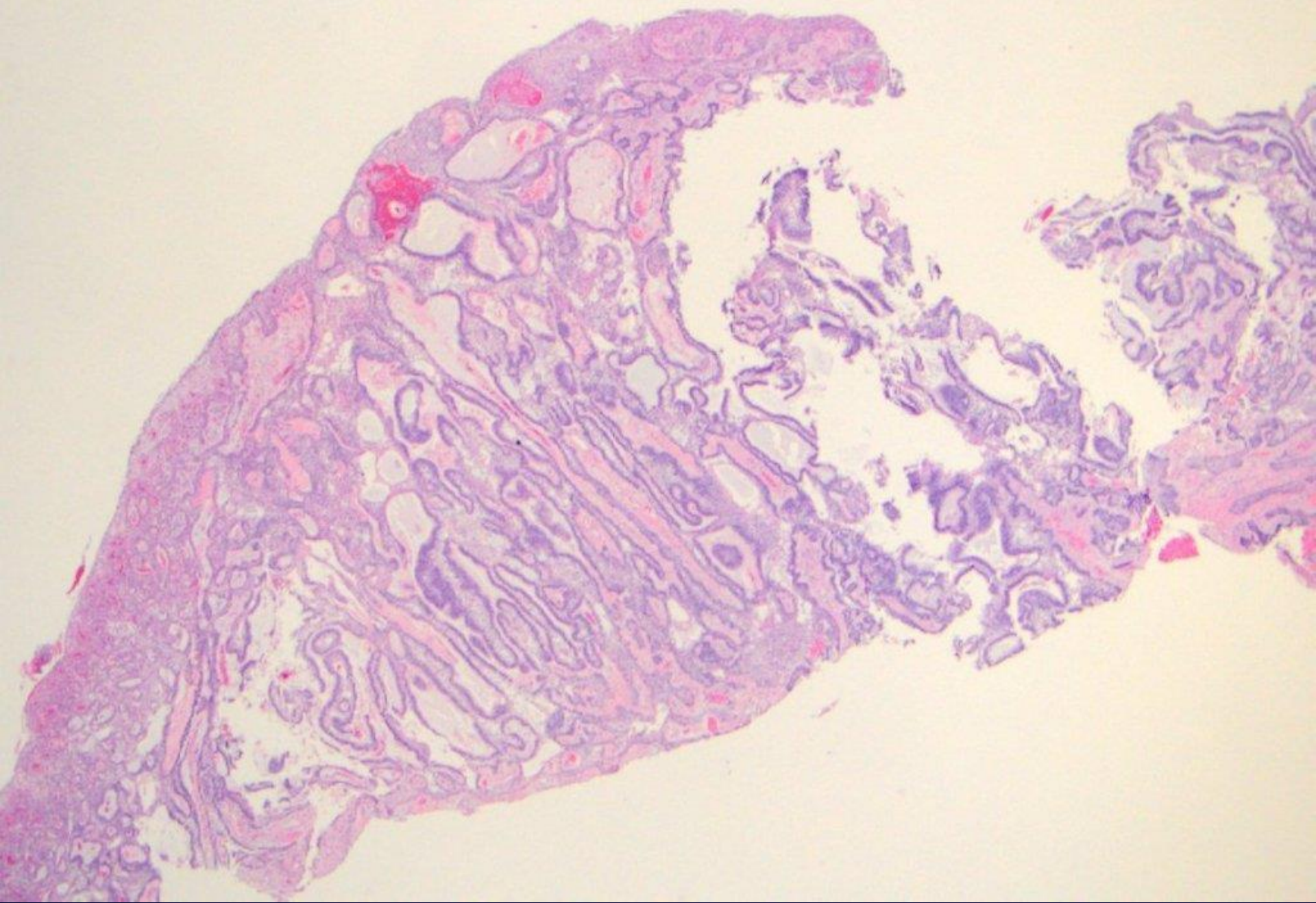




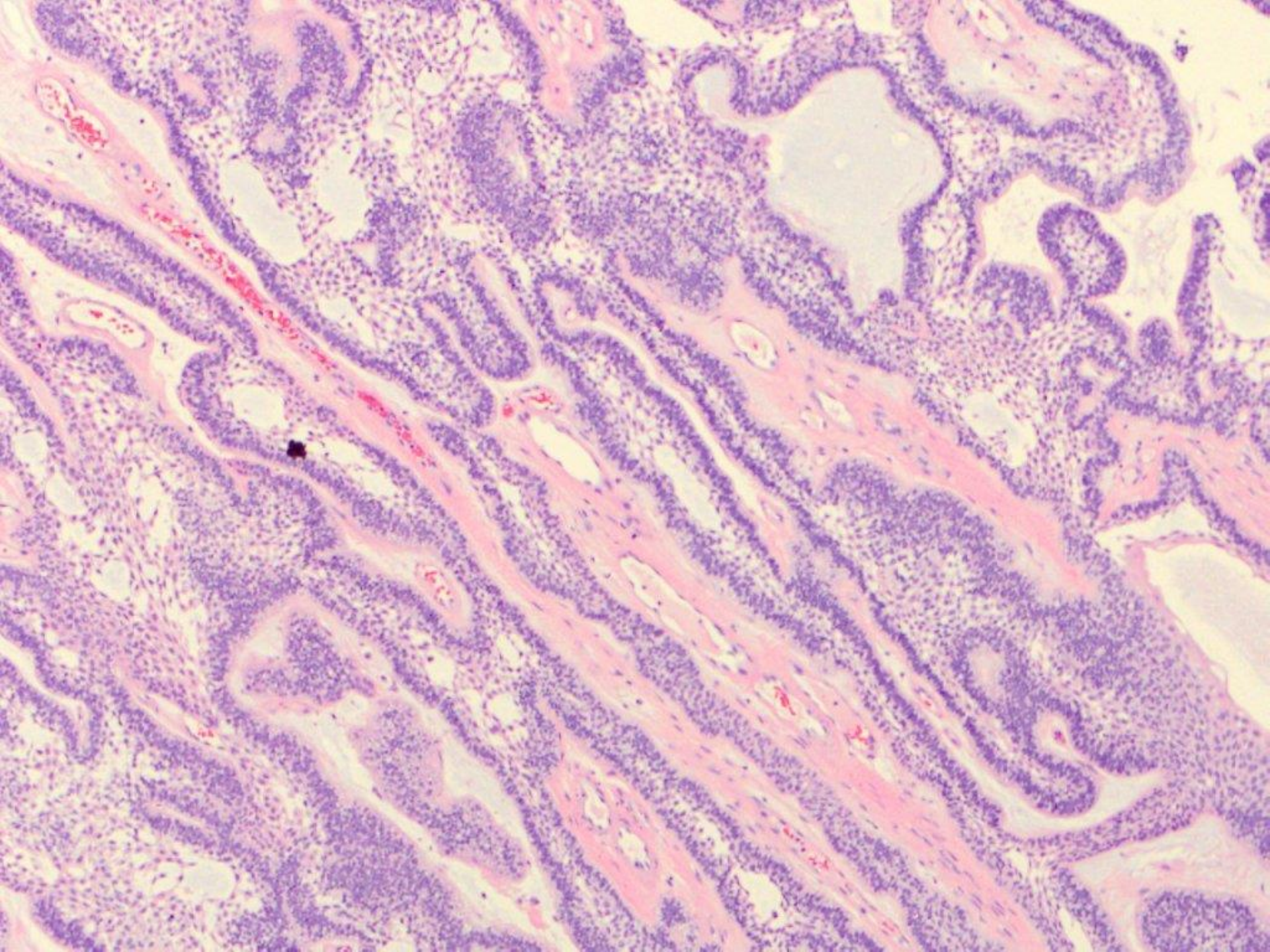


fibroma (patient has multiple keloids; the collagen here is particularly dense)

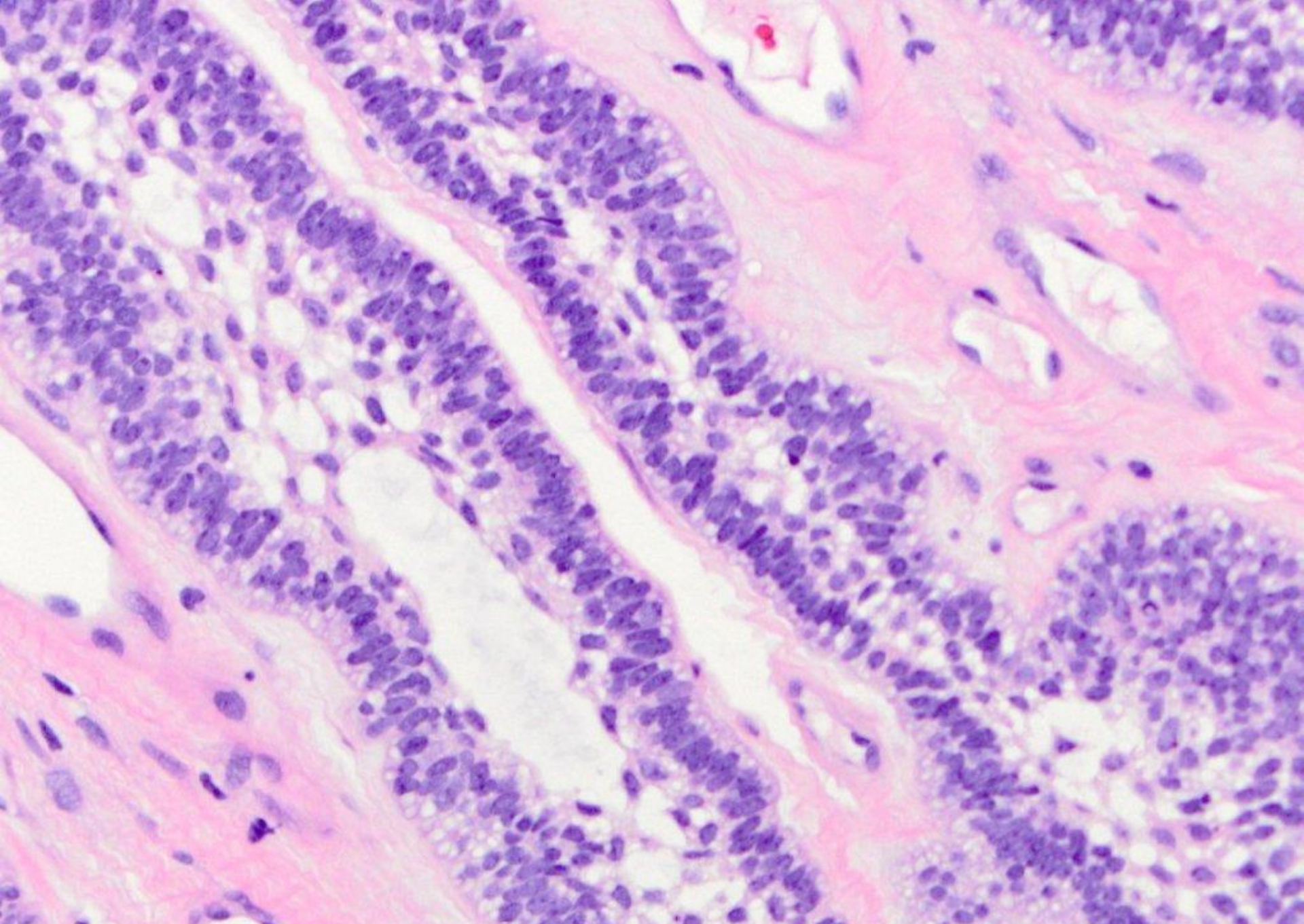






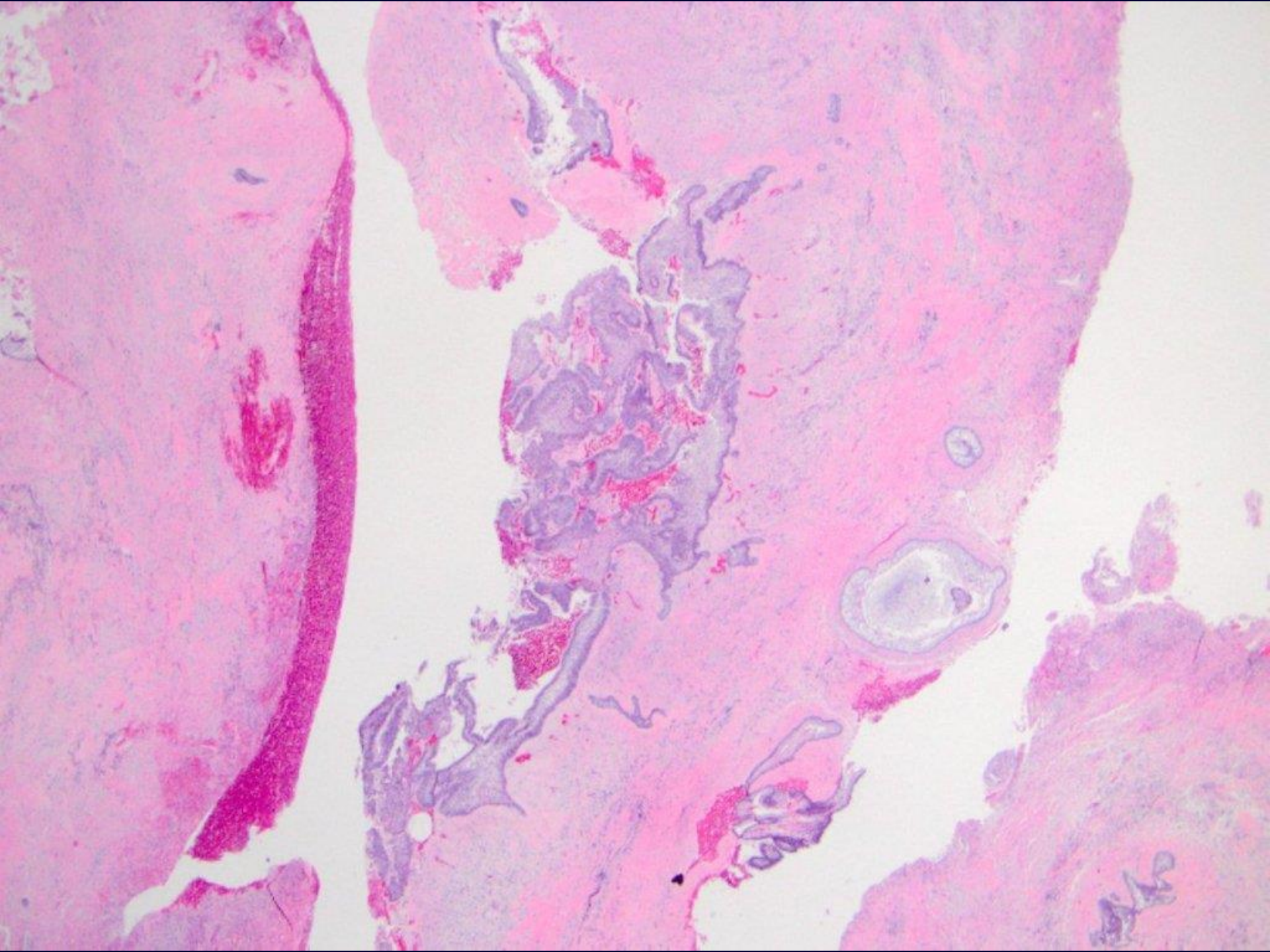




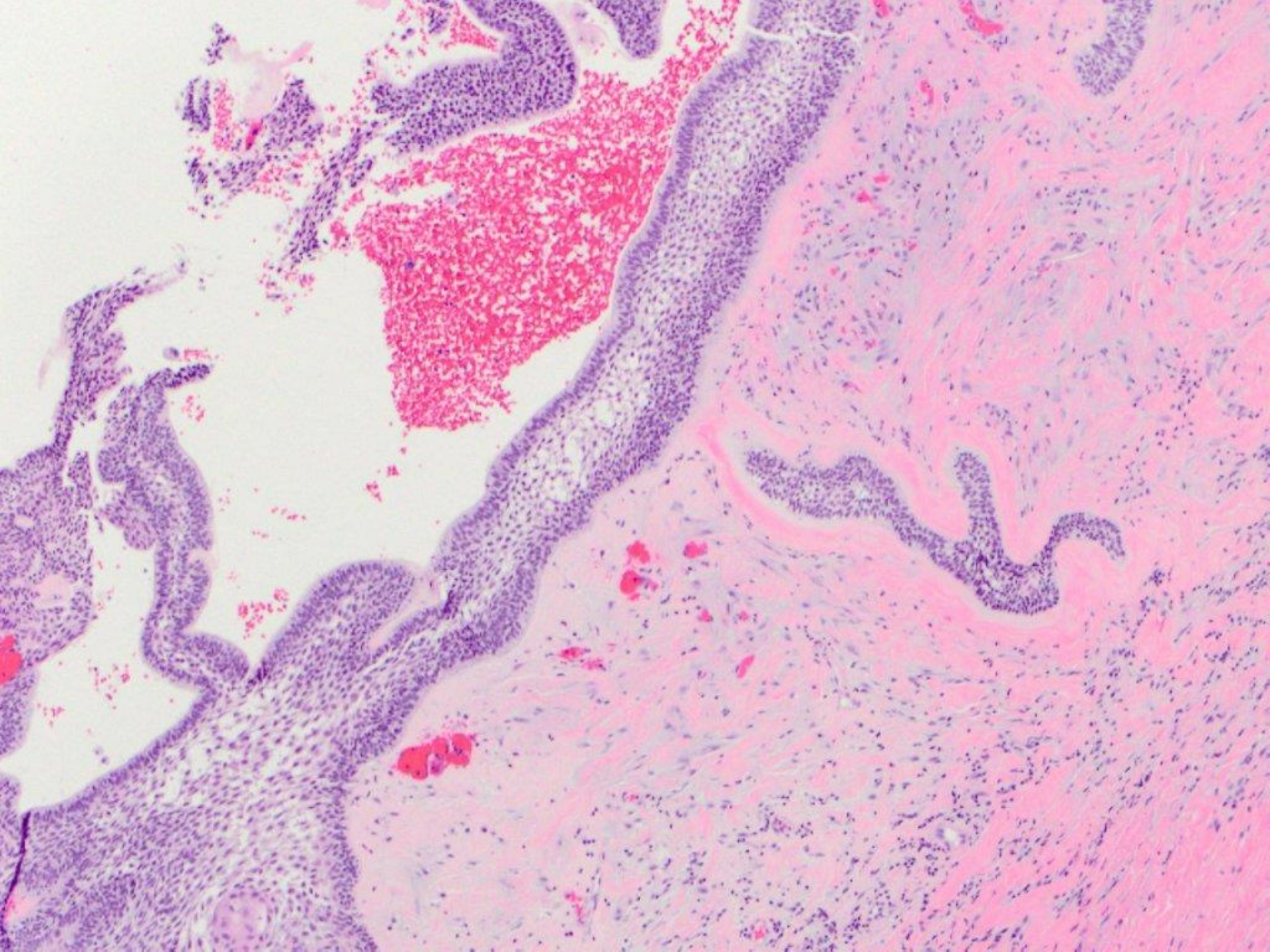


ameloblastoma

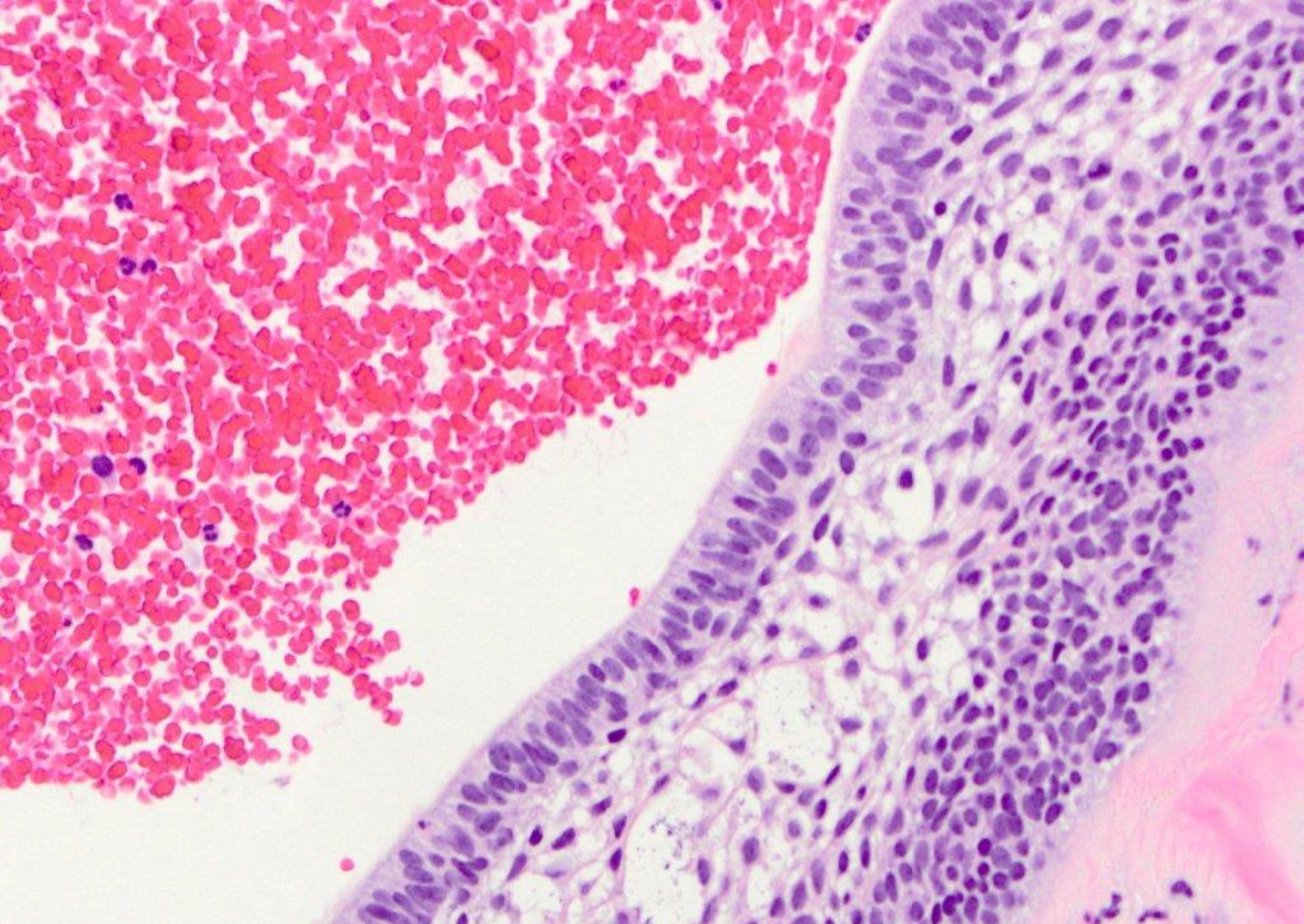






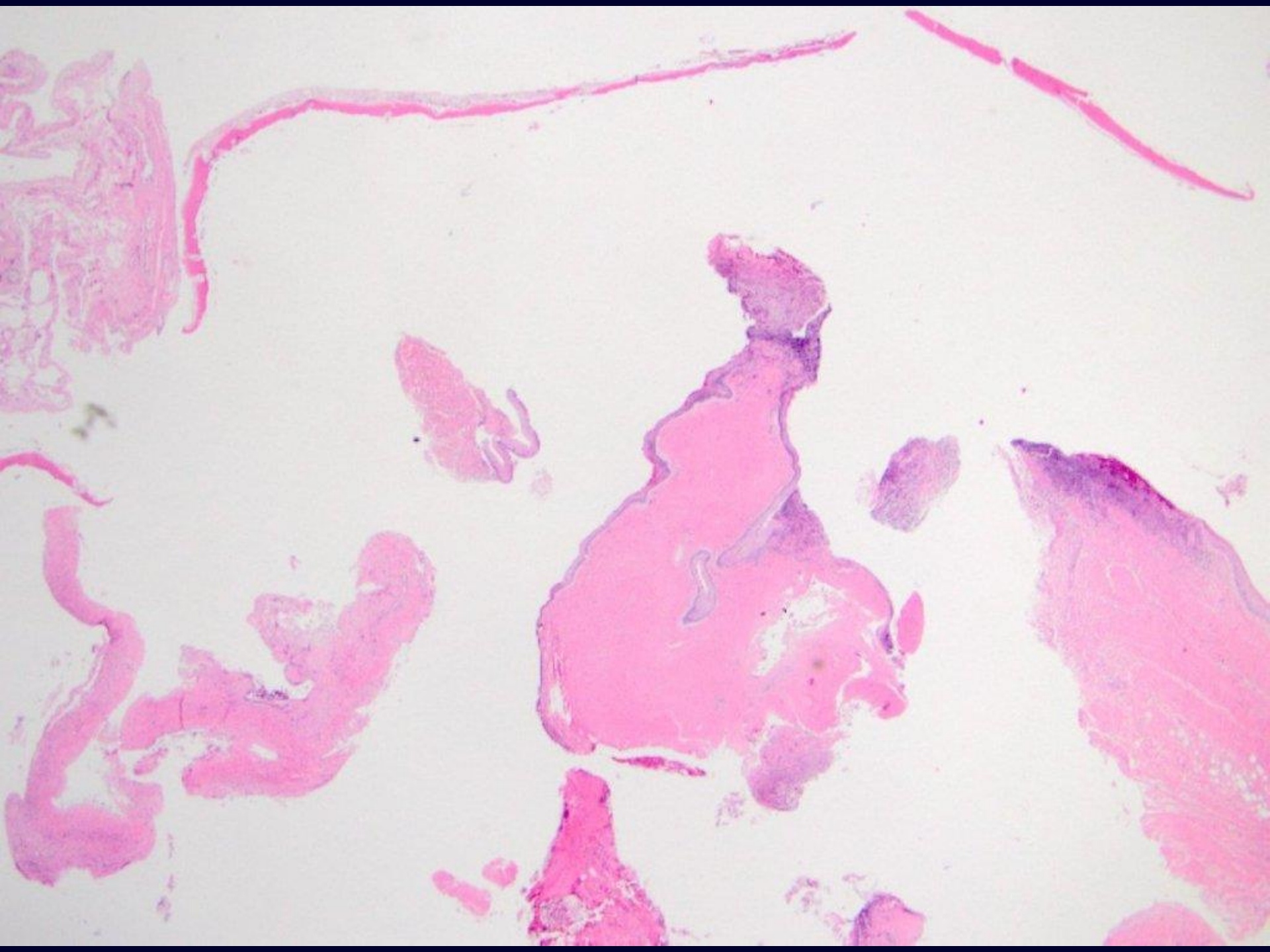




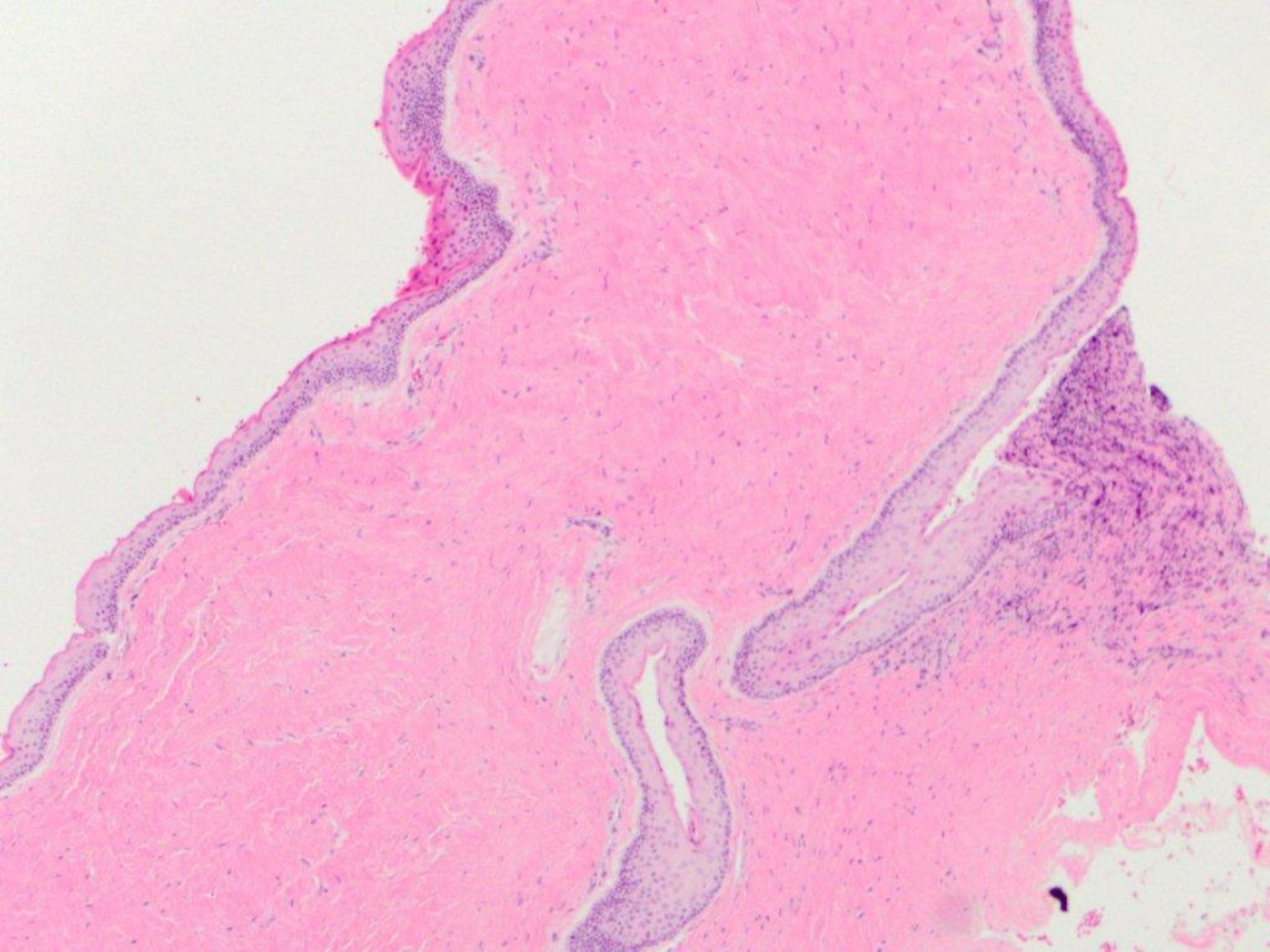

ameloblastoma

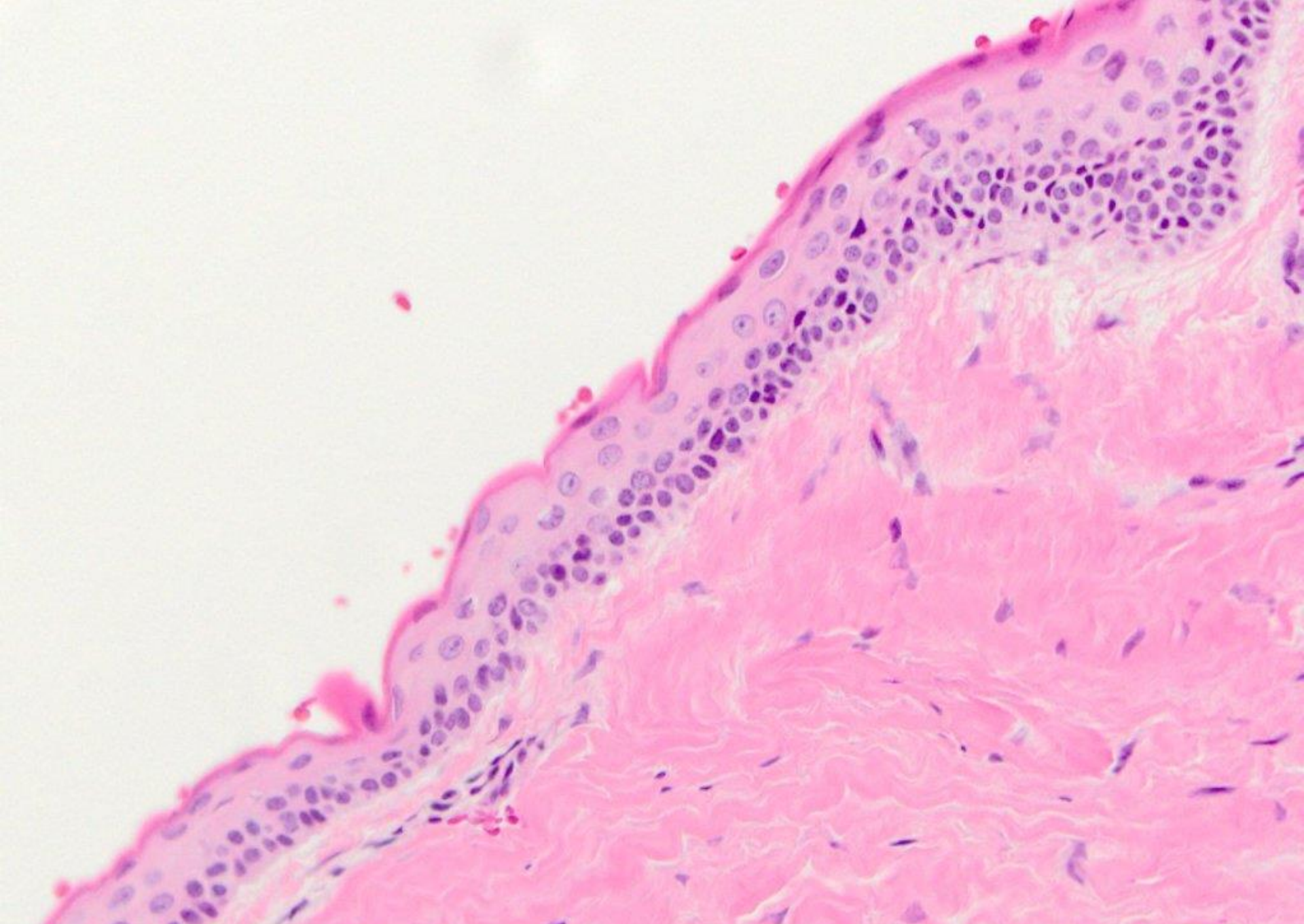






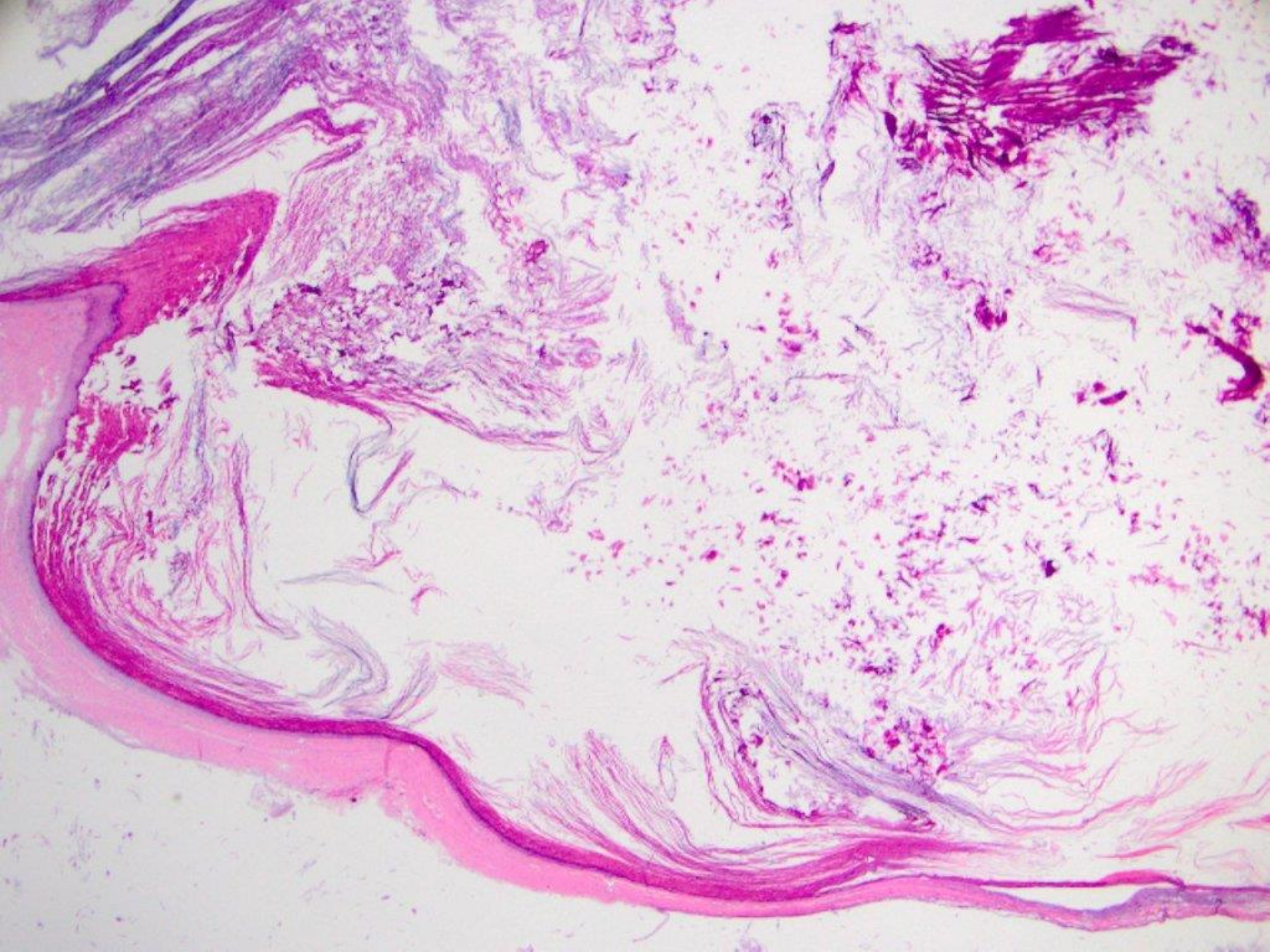




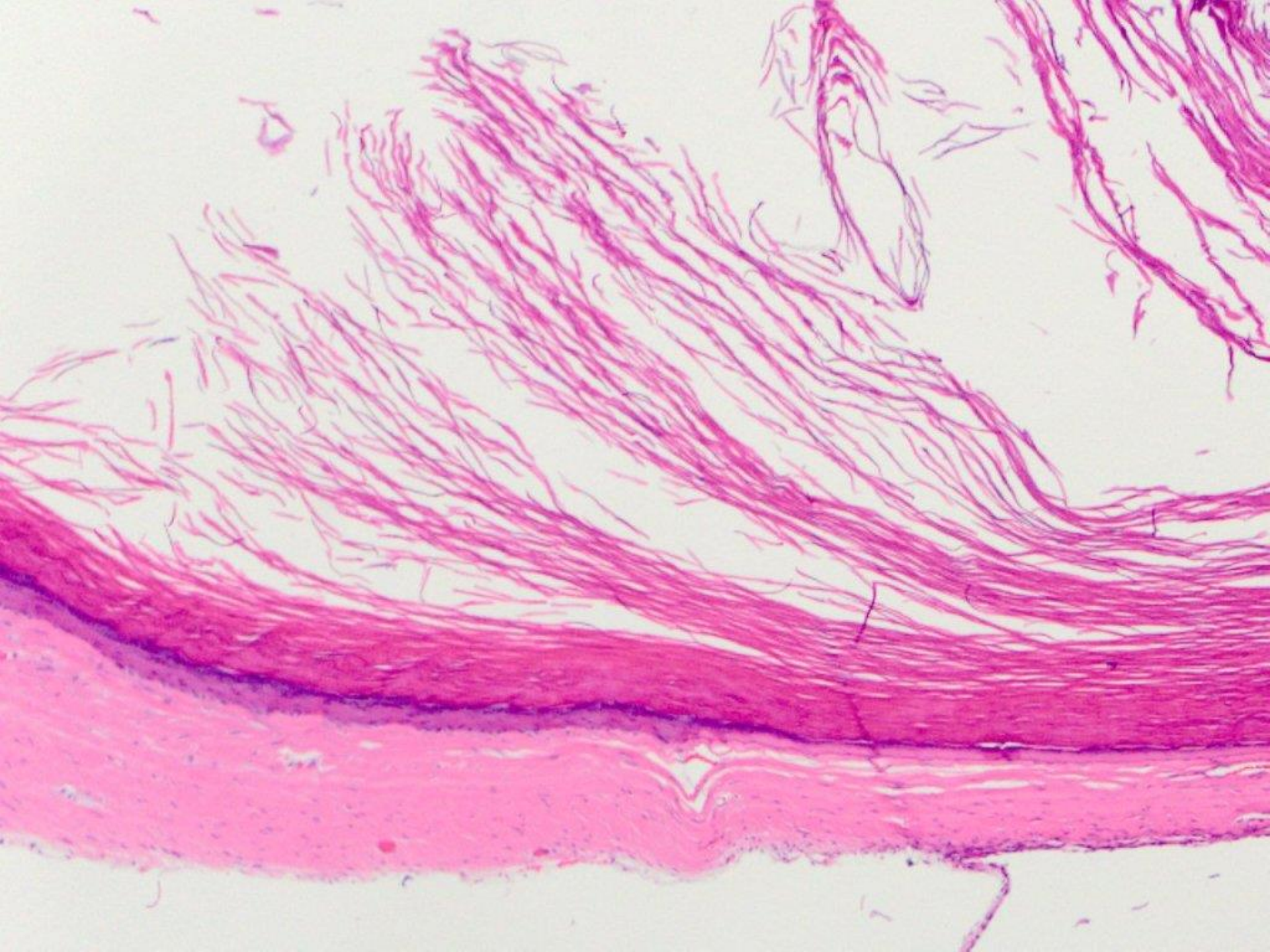


odontogenic keratocyst (keratocystic odontogenic tumor)

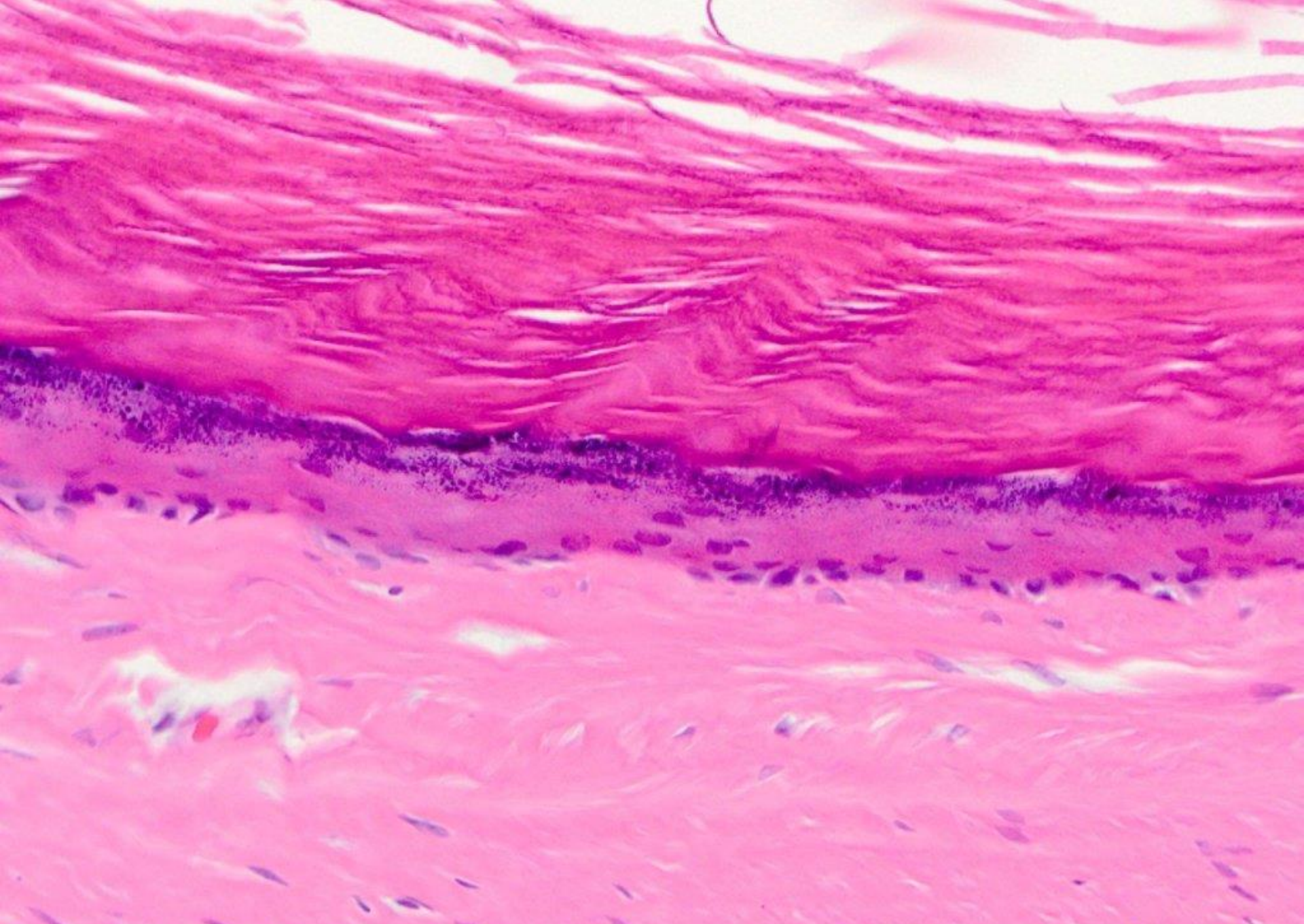






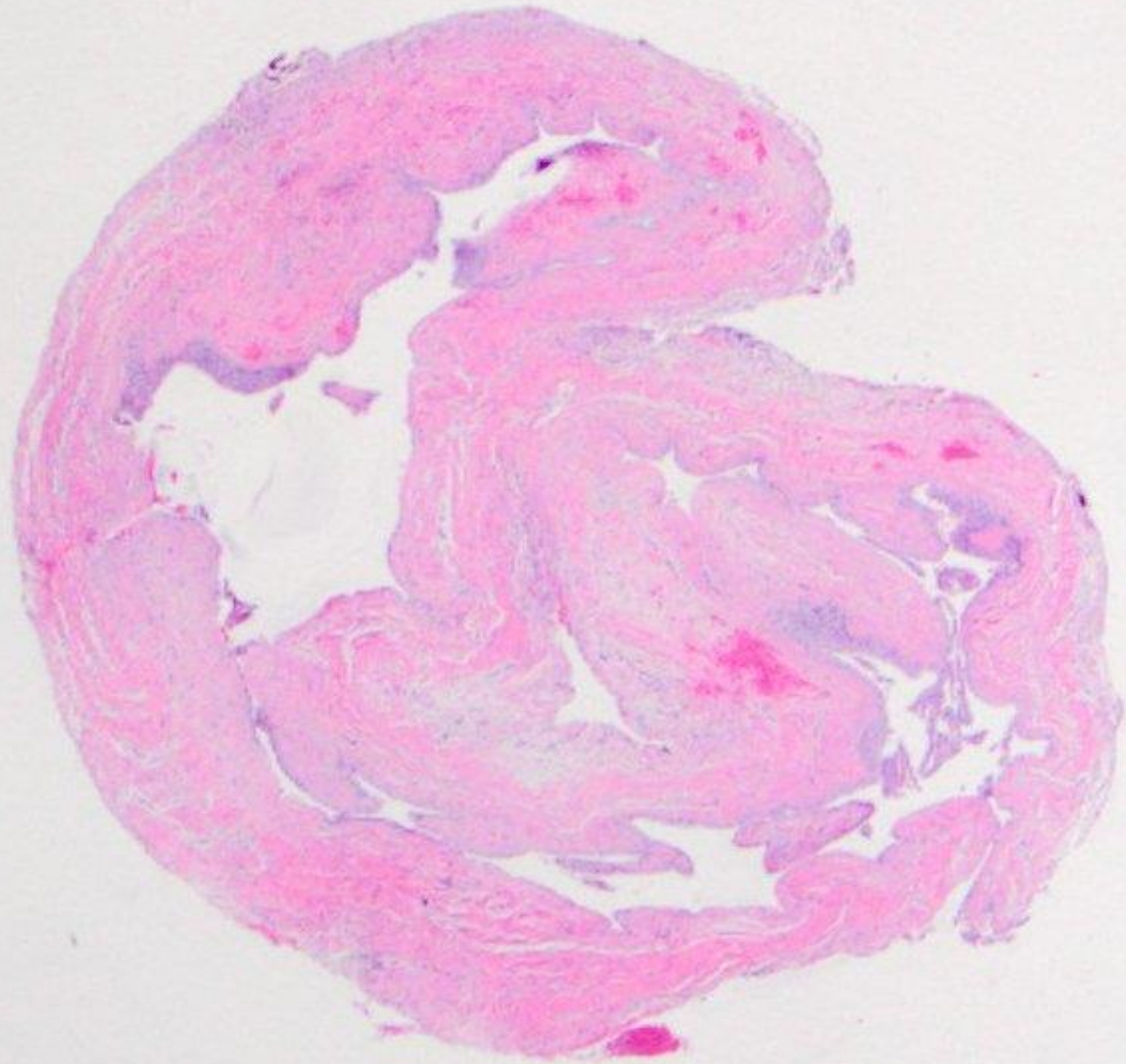




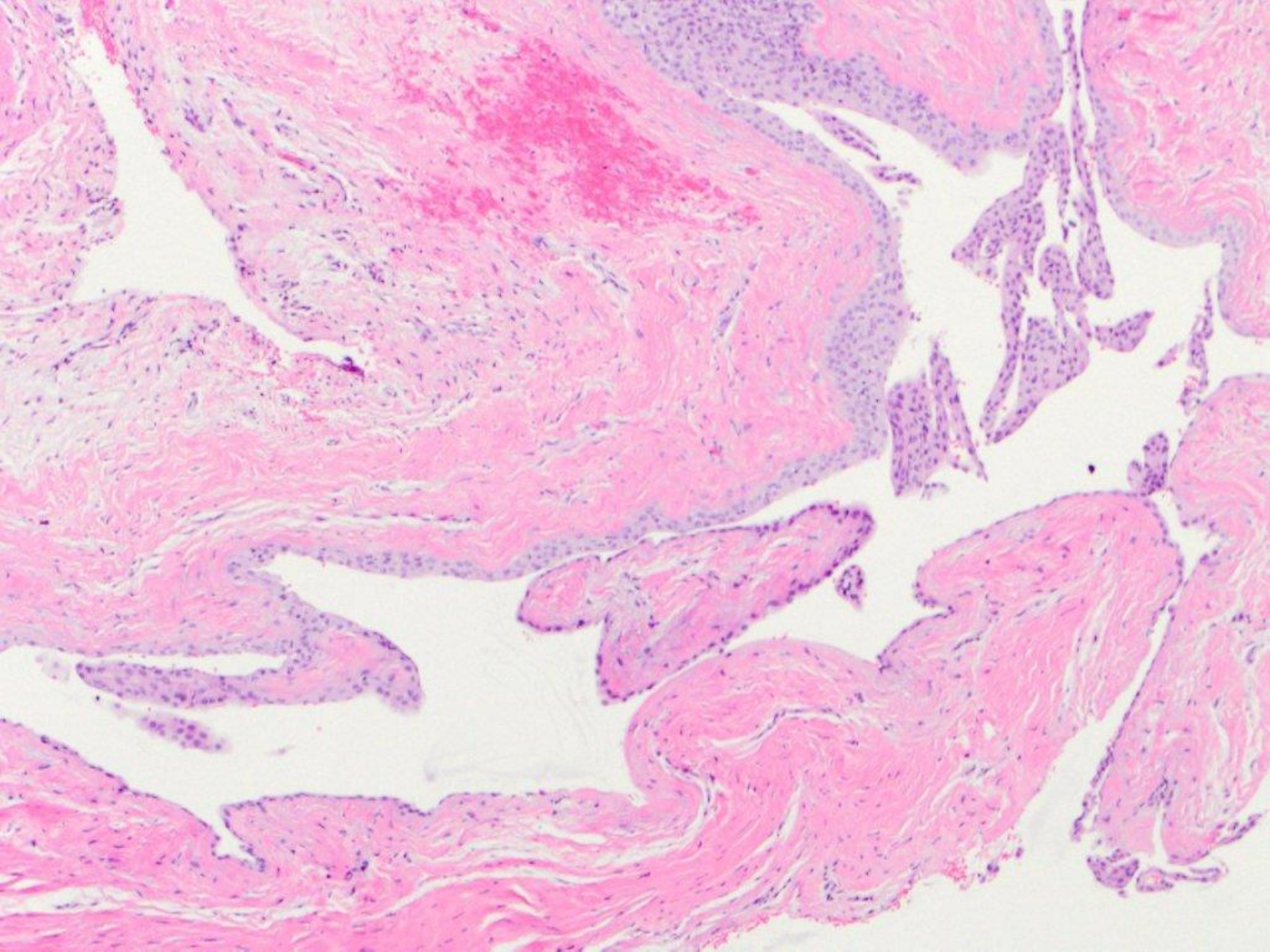


orthokeratinizing odontogenic cyst

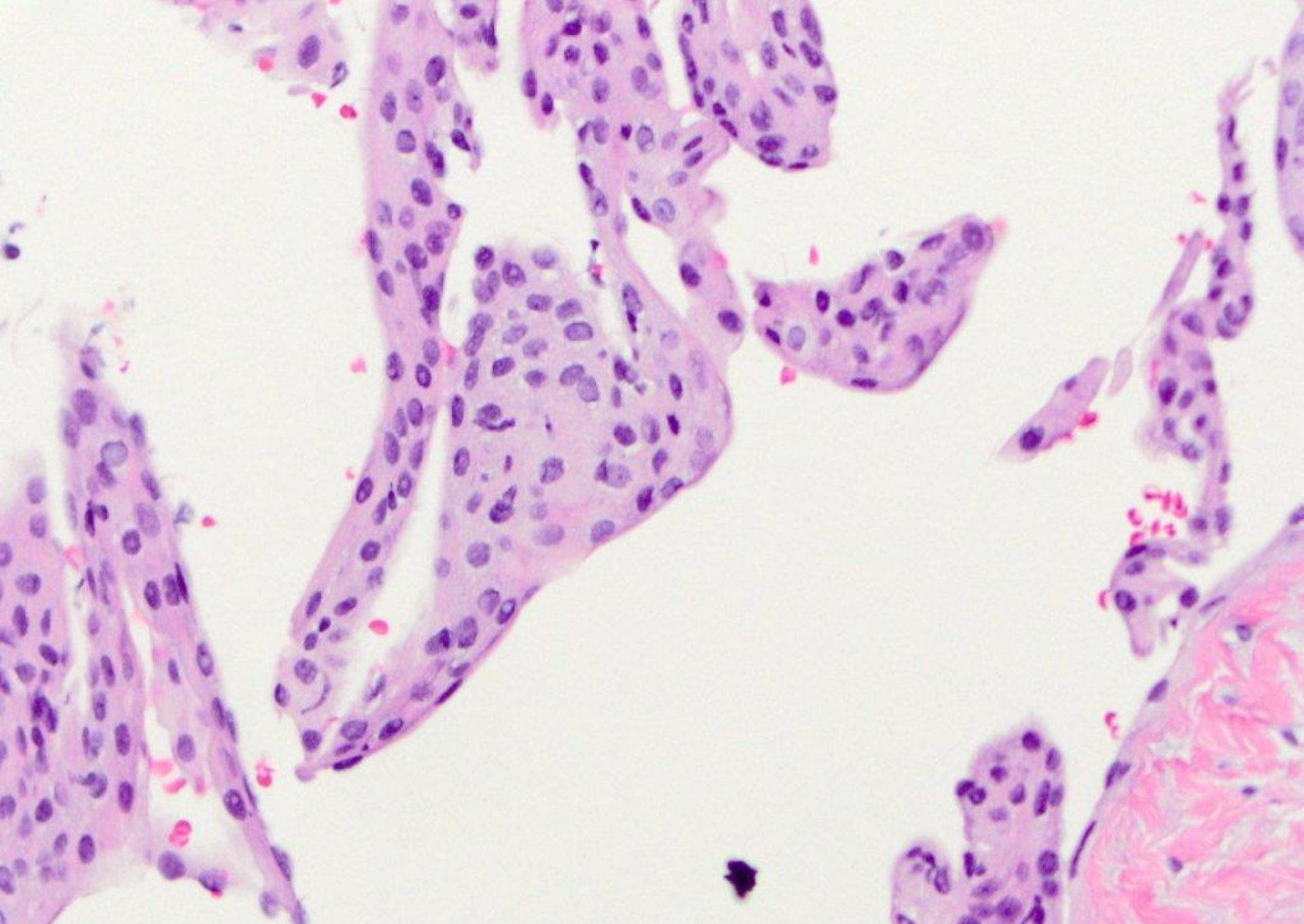






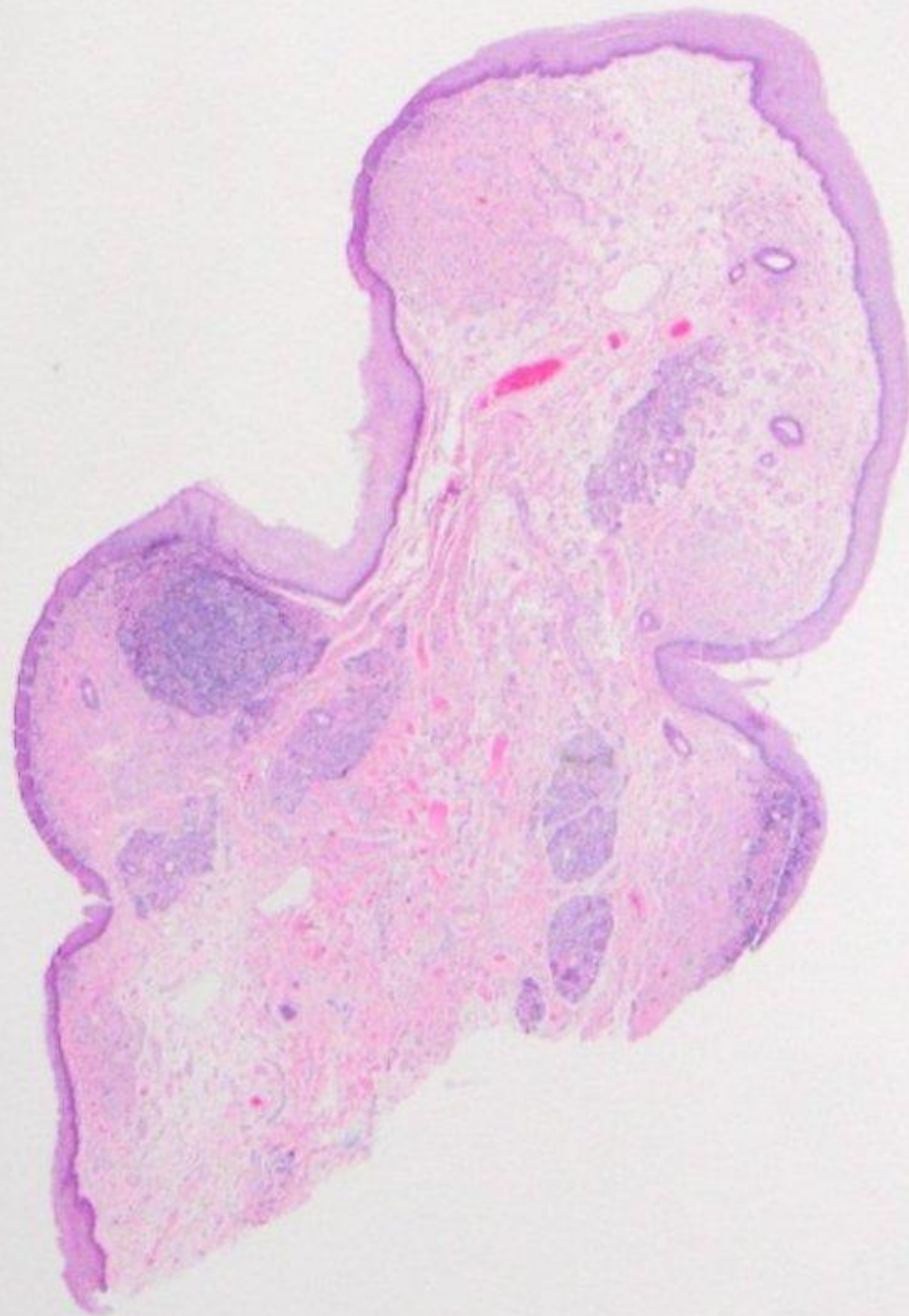




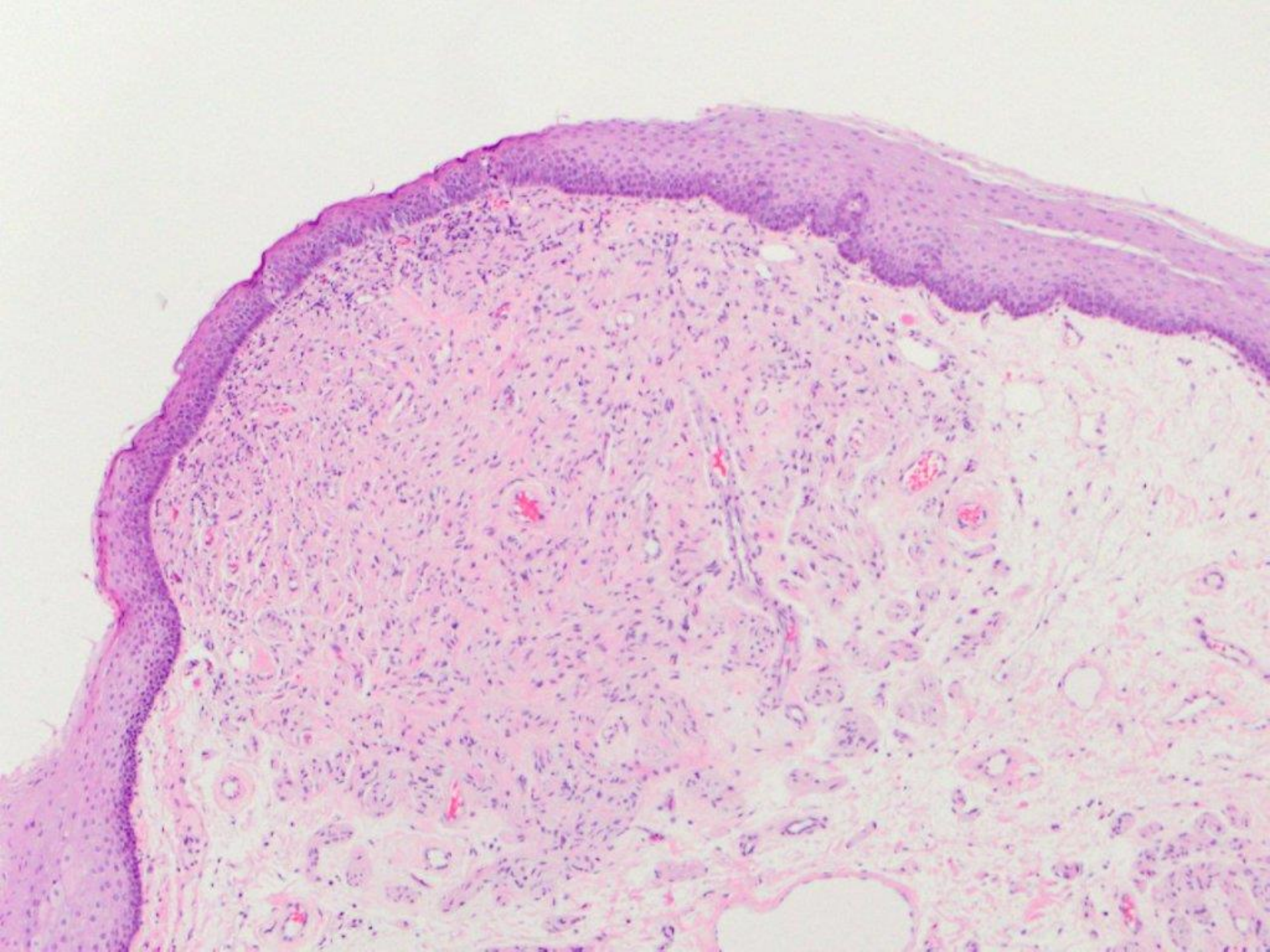


lateral periodontal cyst

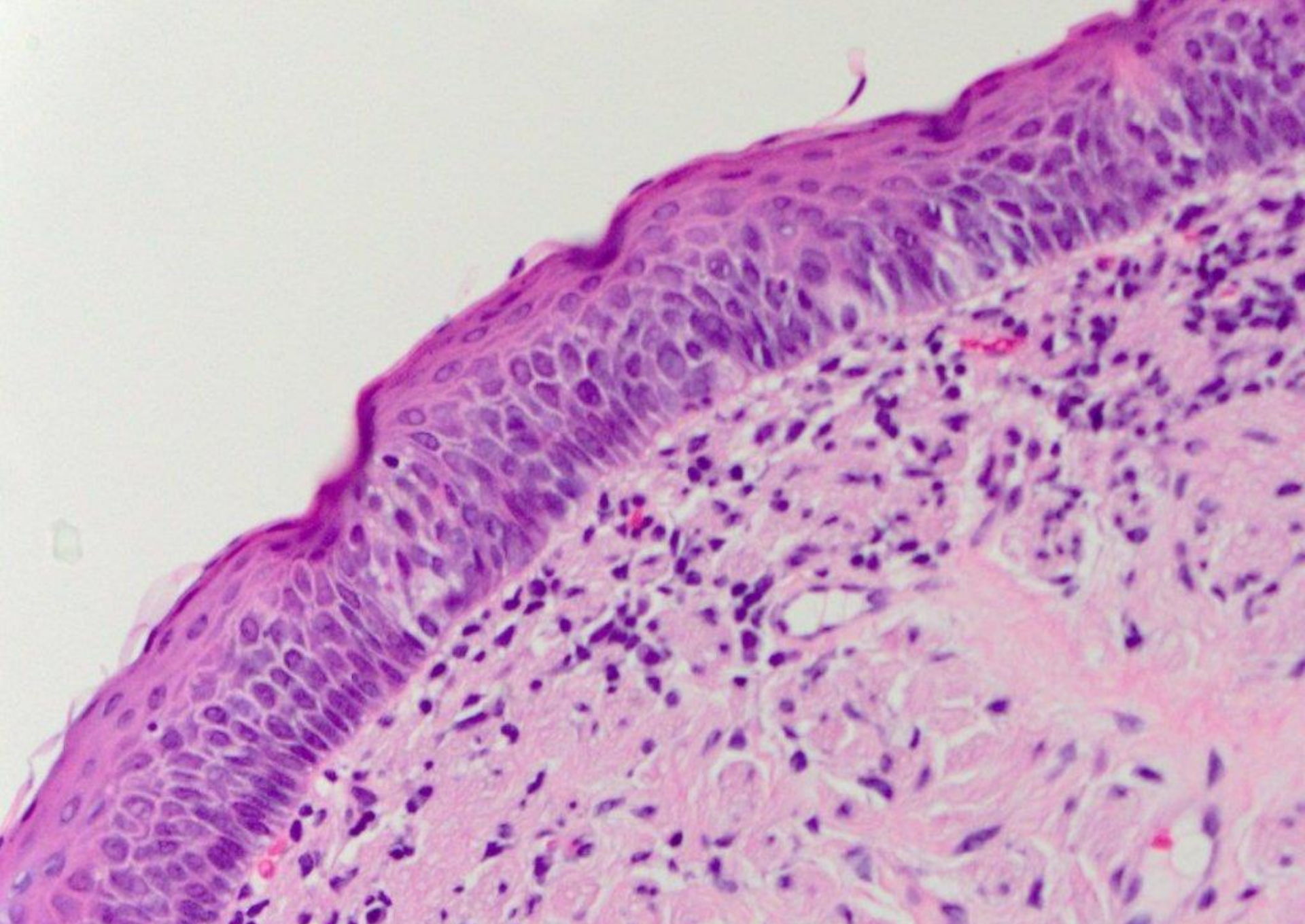






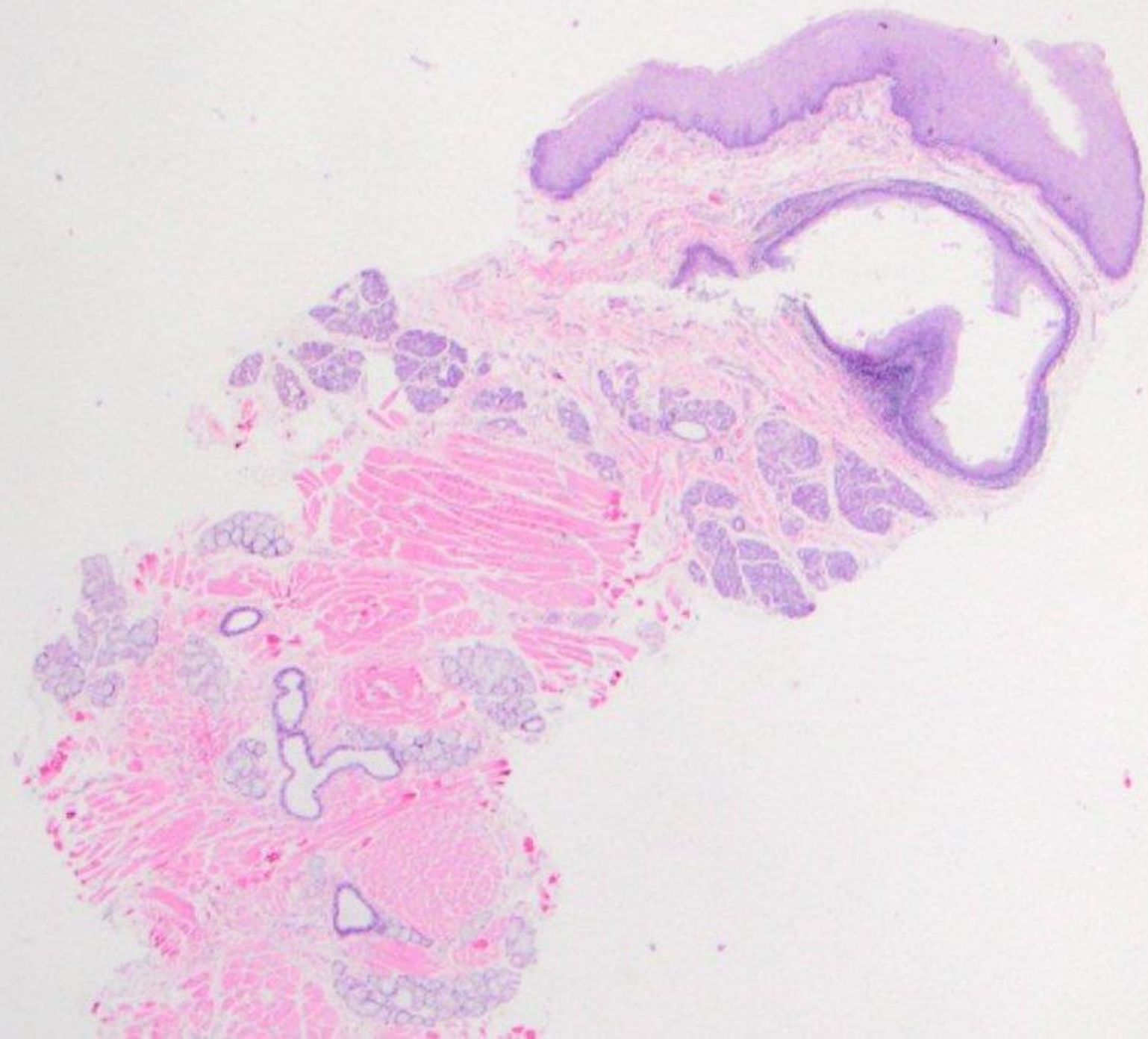




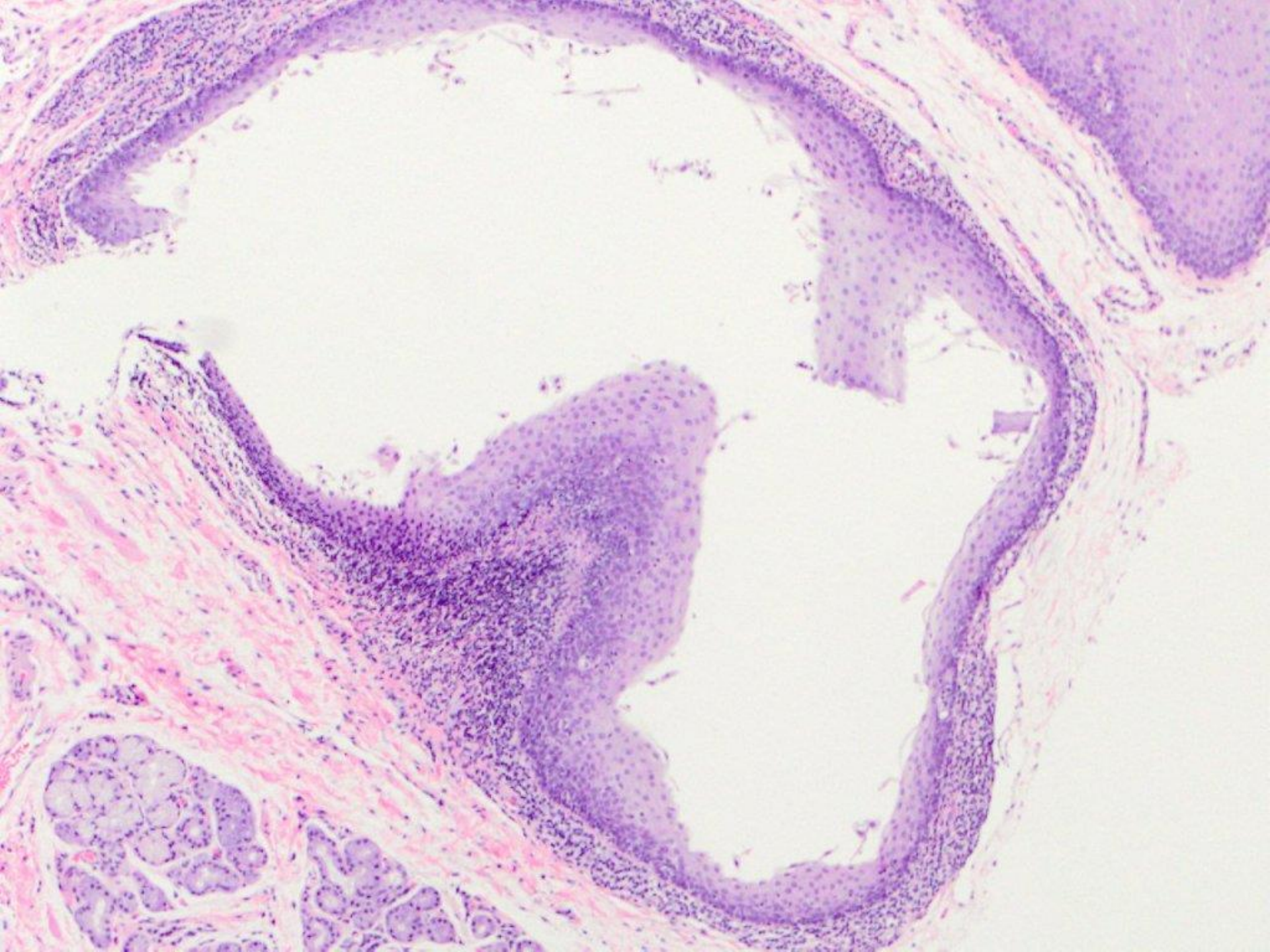


hyperplastic foliate papilla (with taste buds, neural plexus, and lymphoid aggregate)

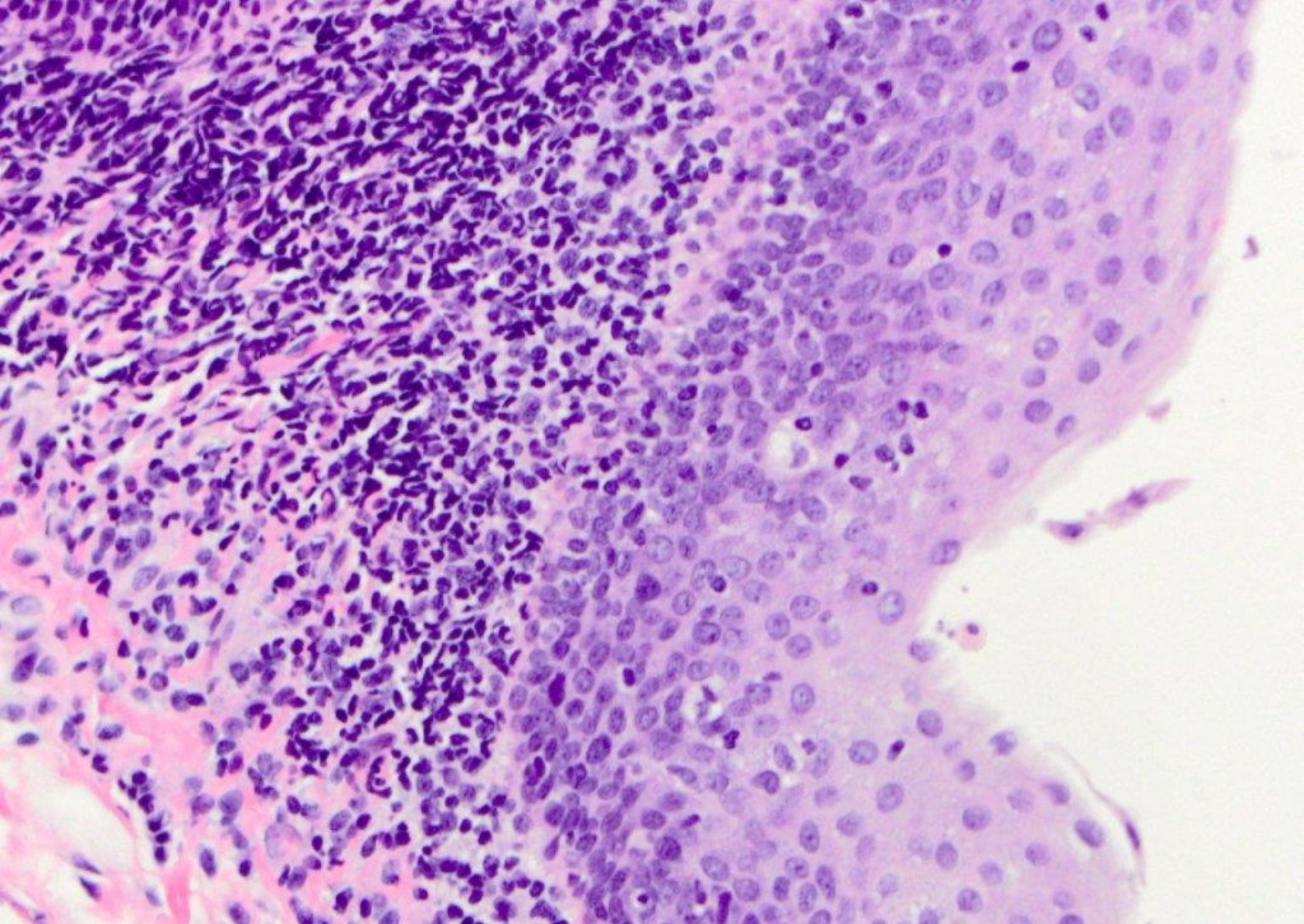






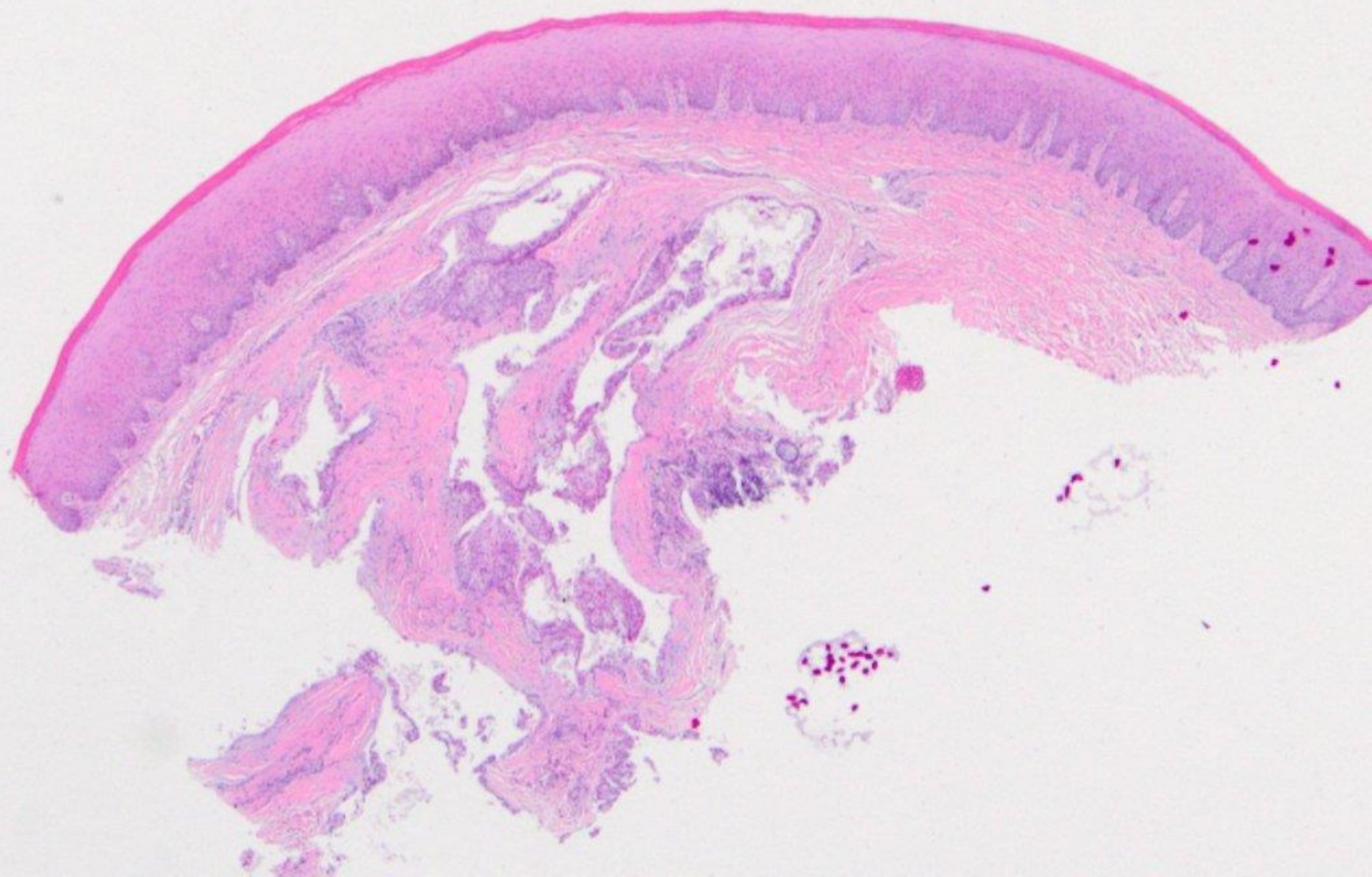




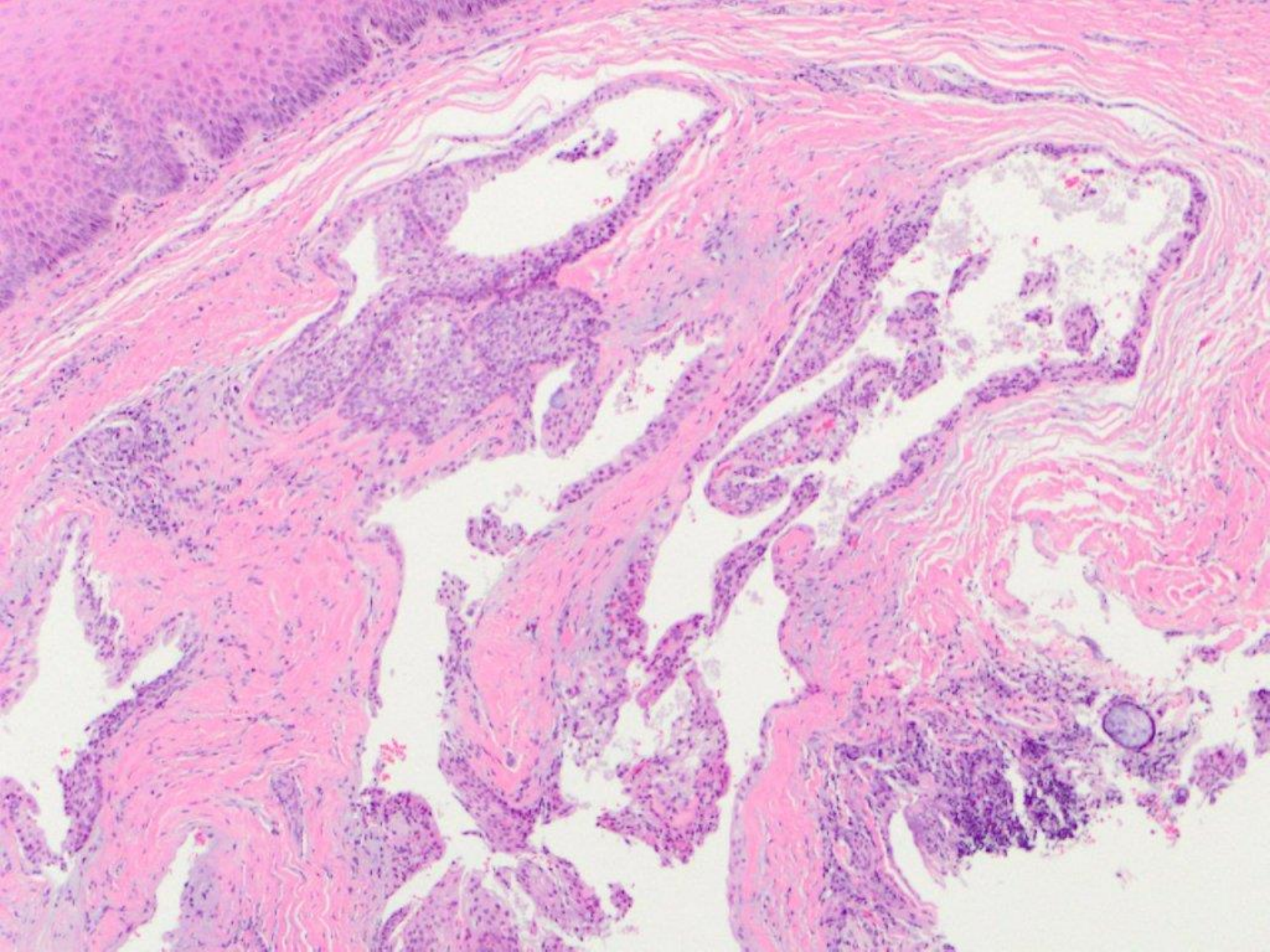


lymphoepithelial cyst, follicle papilla

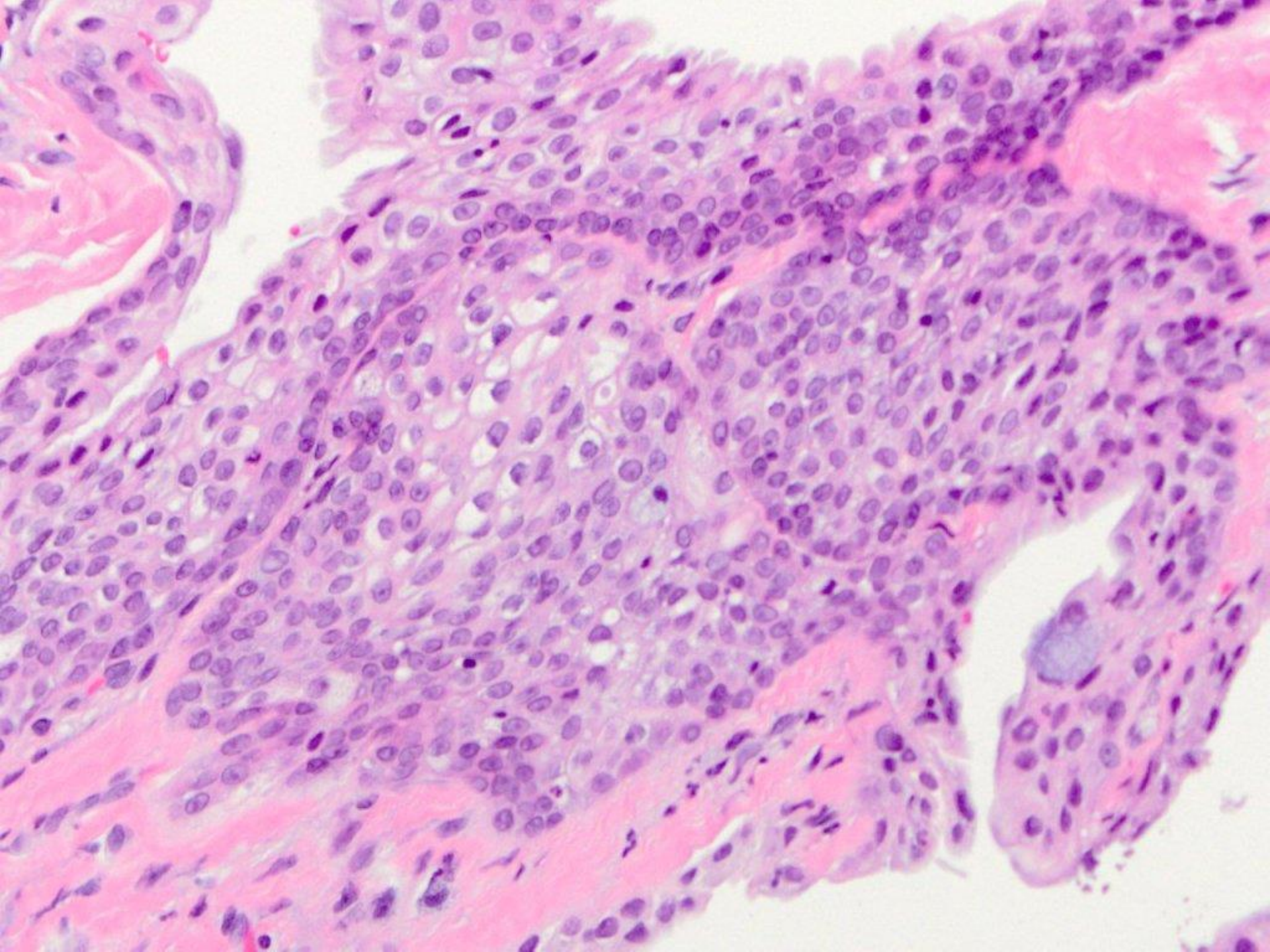




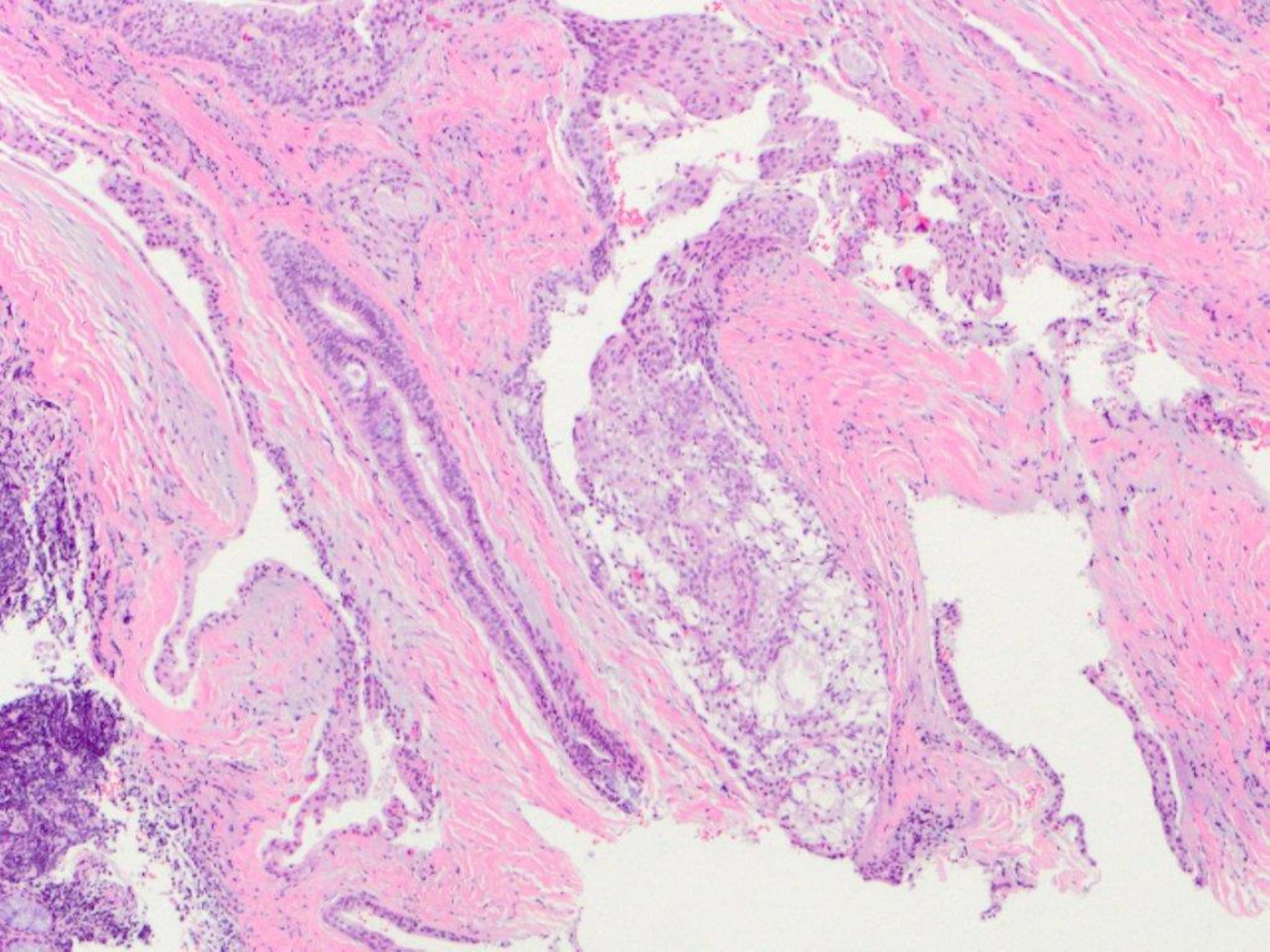




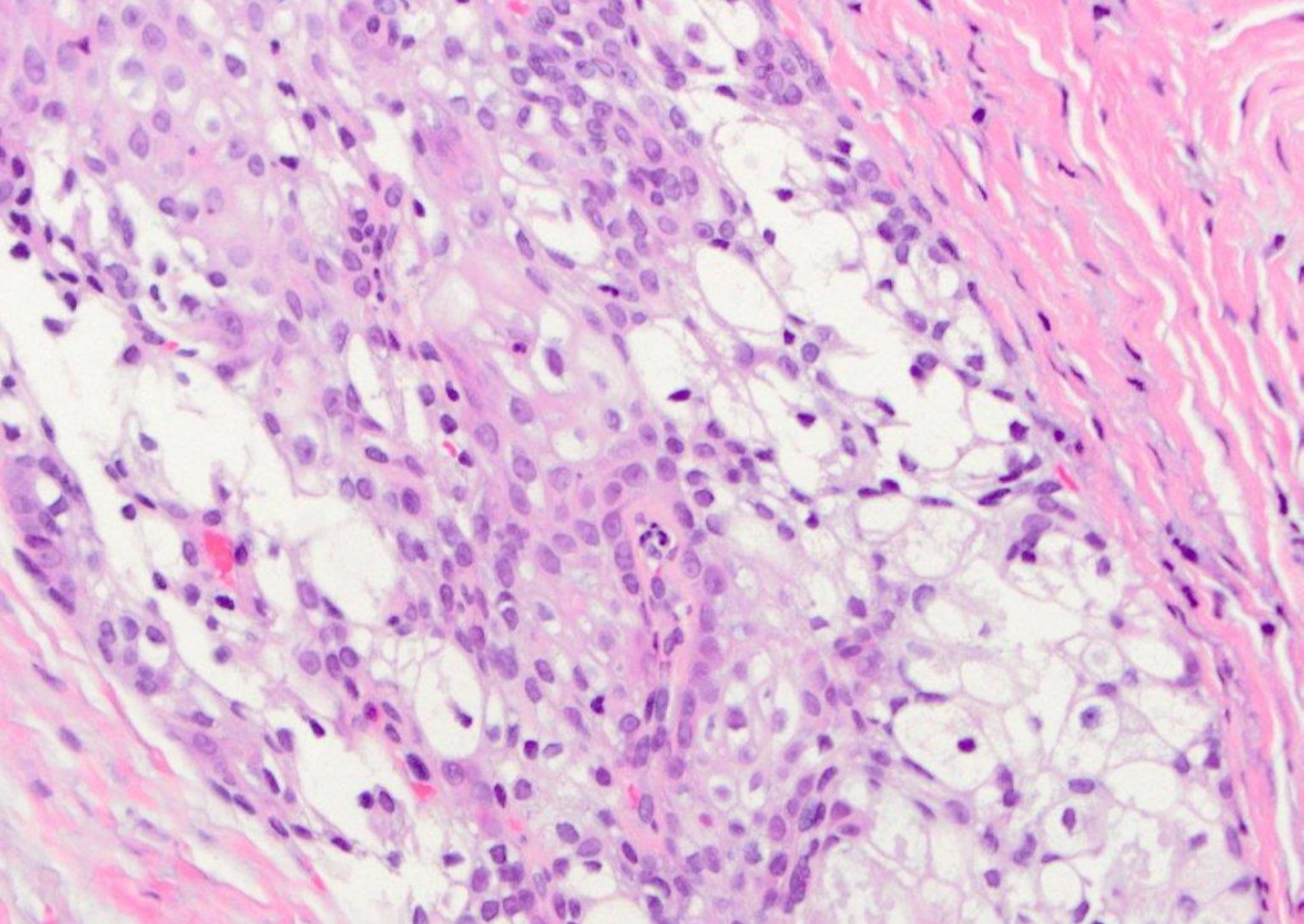






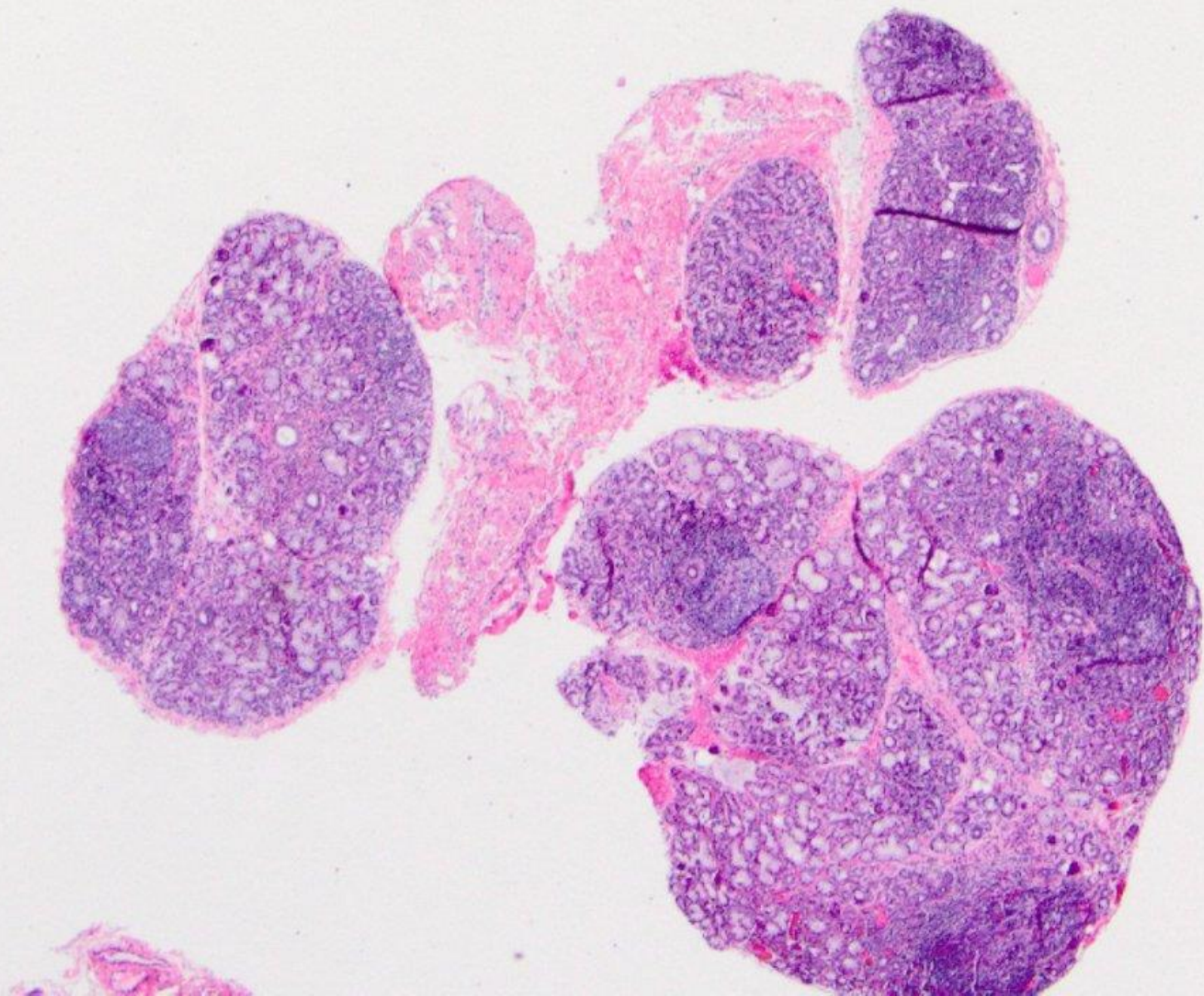




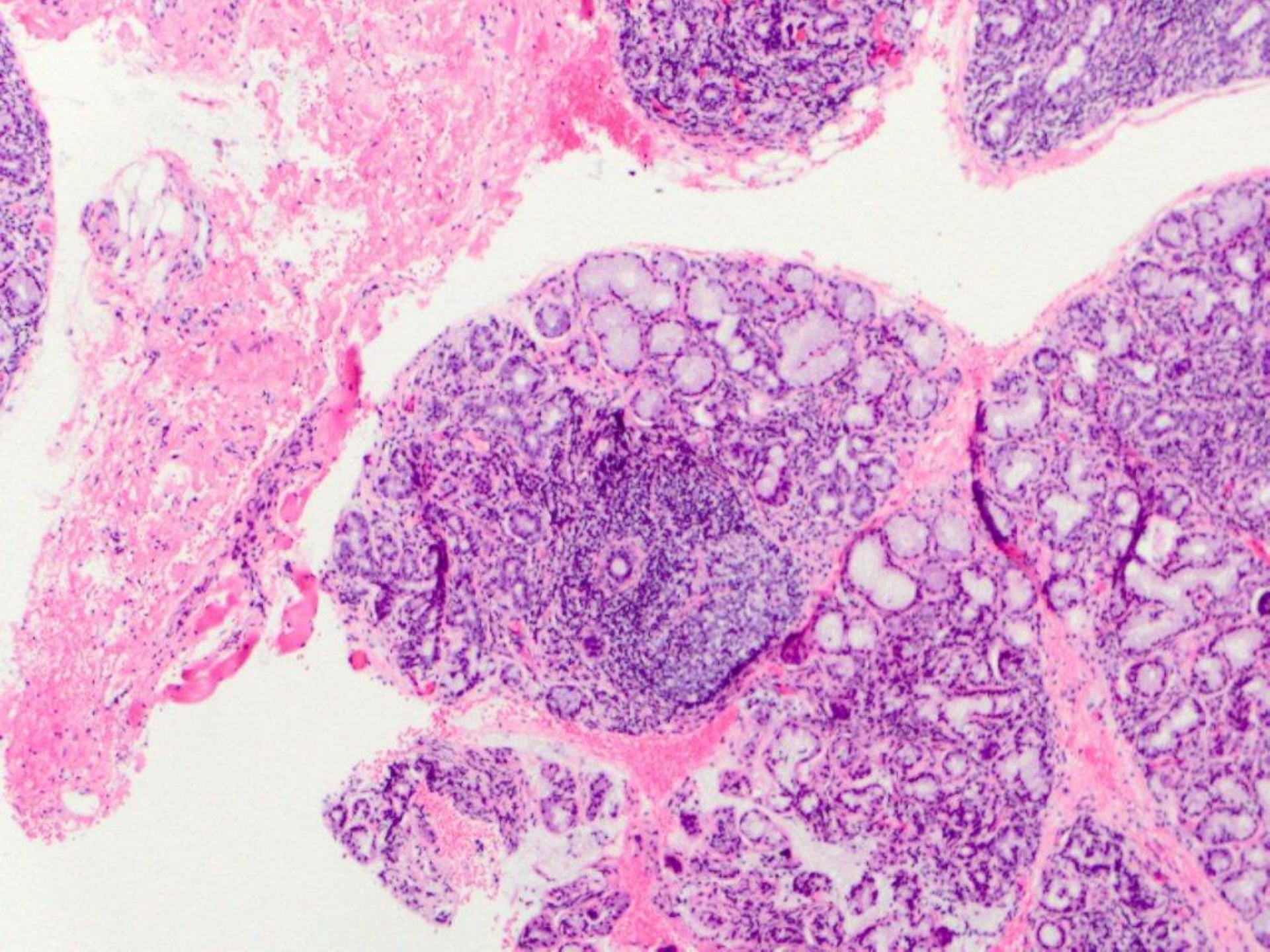


mucoepidermoid carcinoma, palate

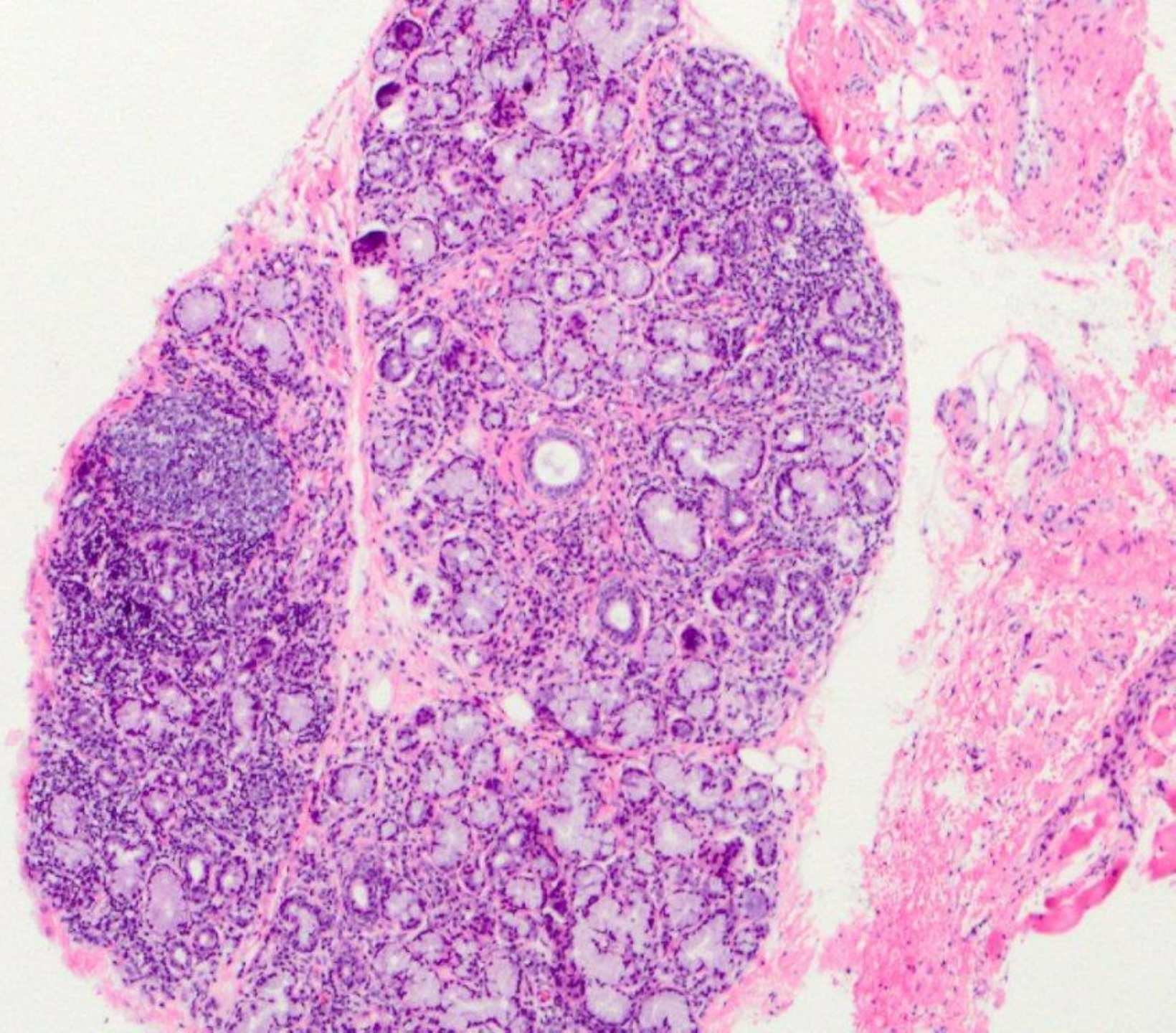




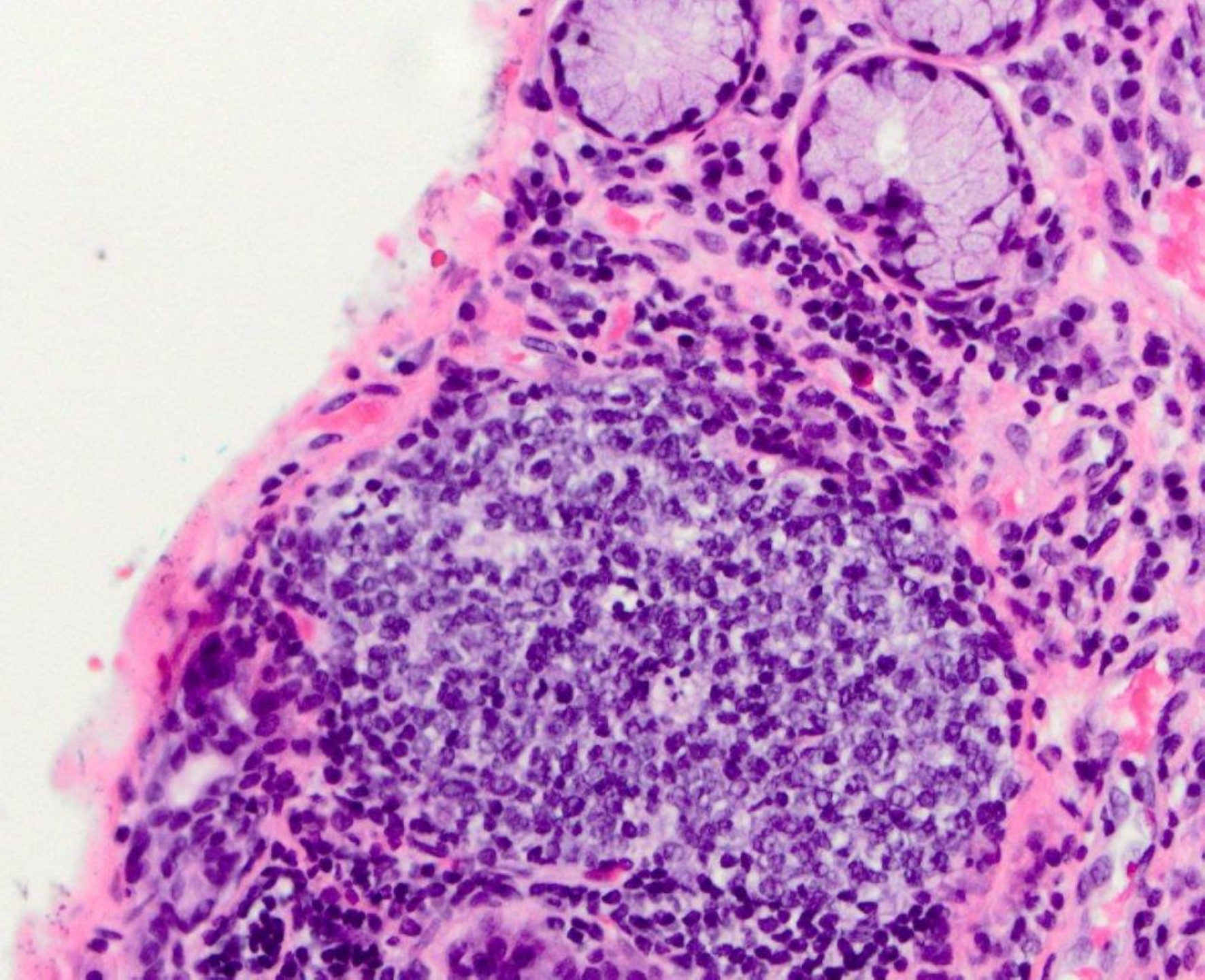




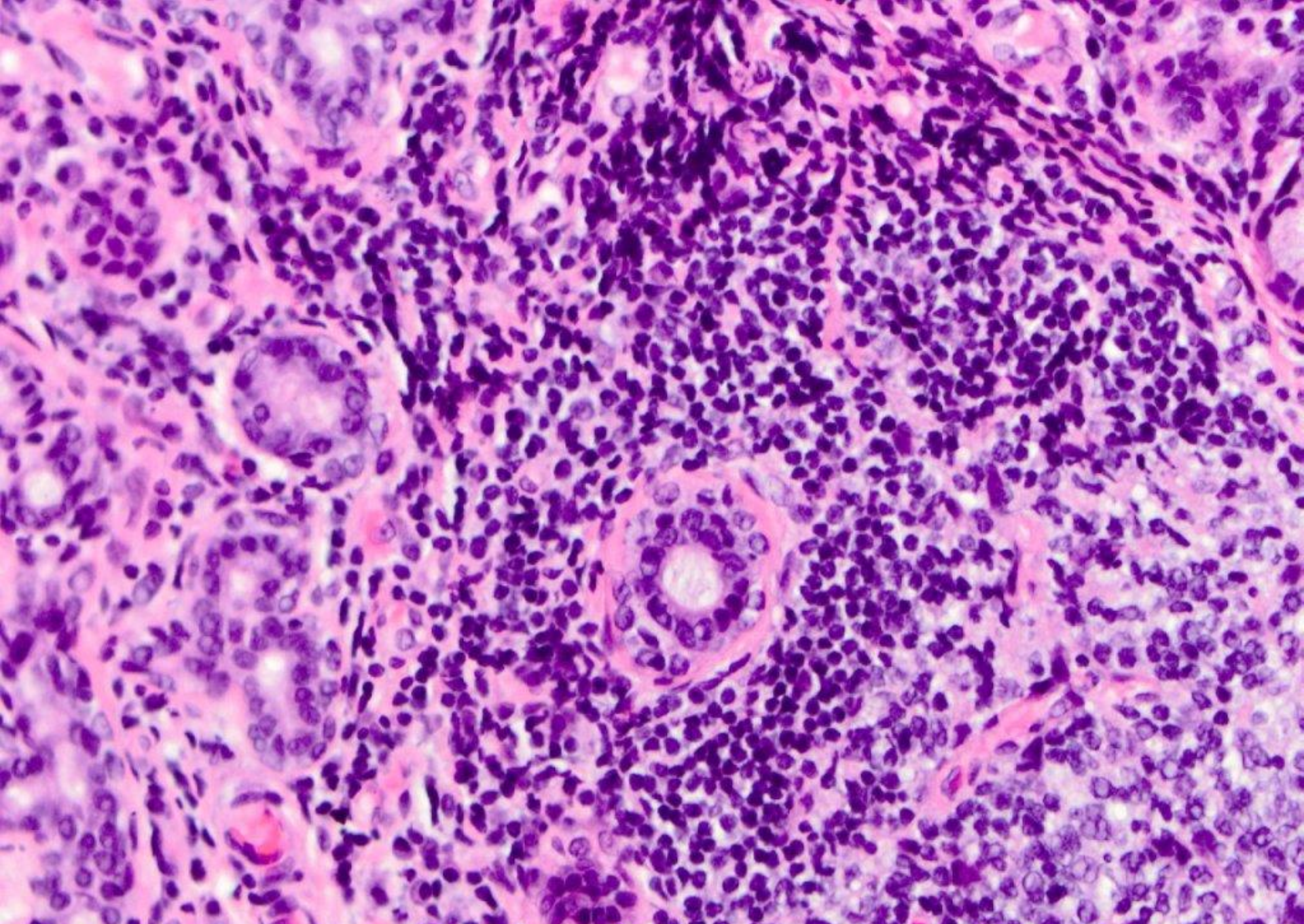






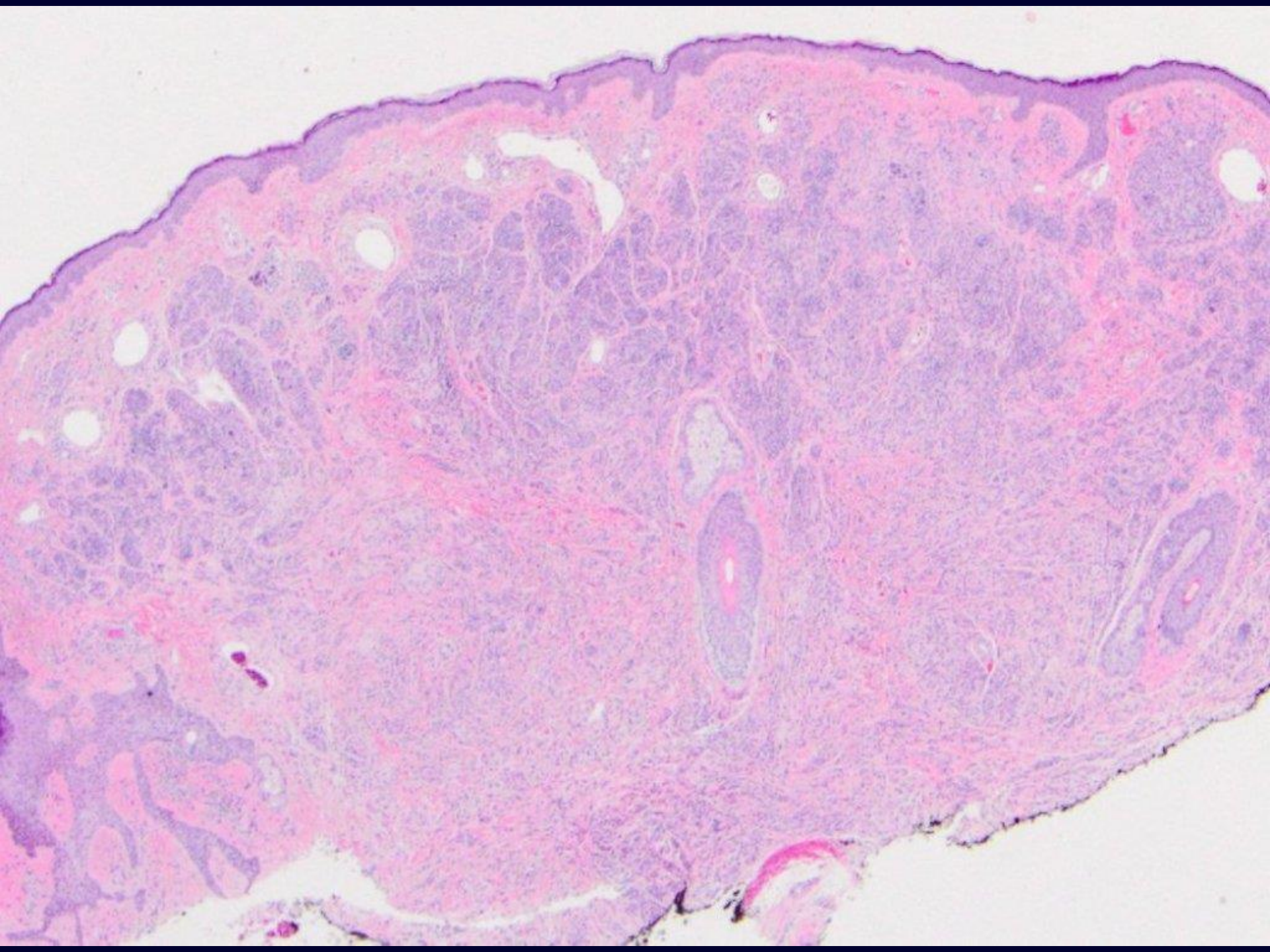




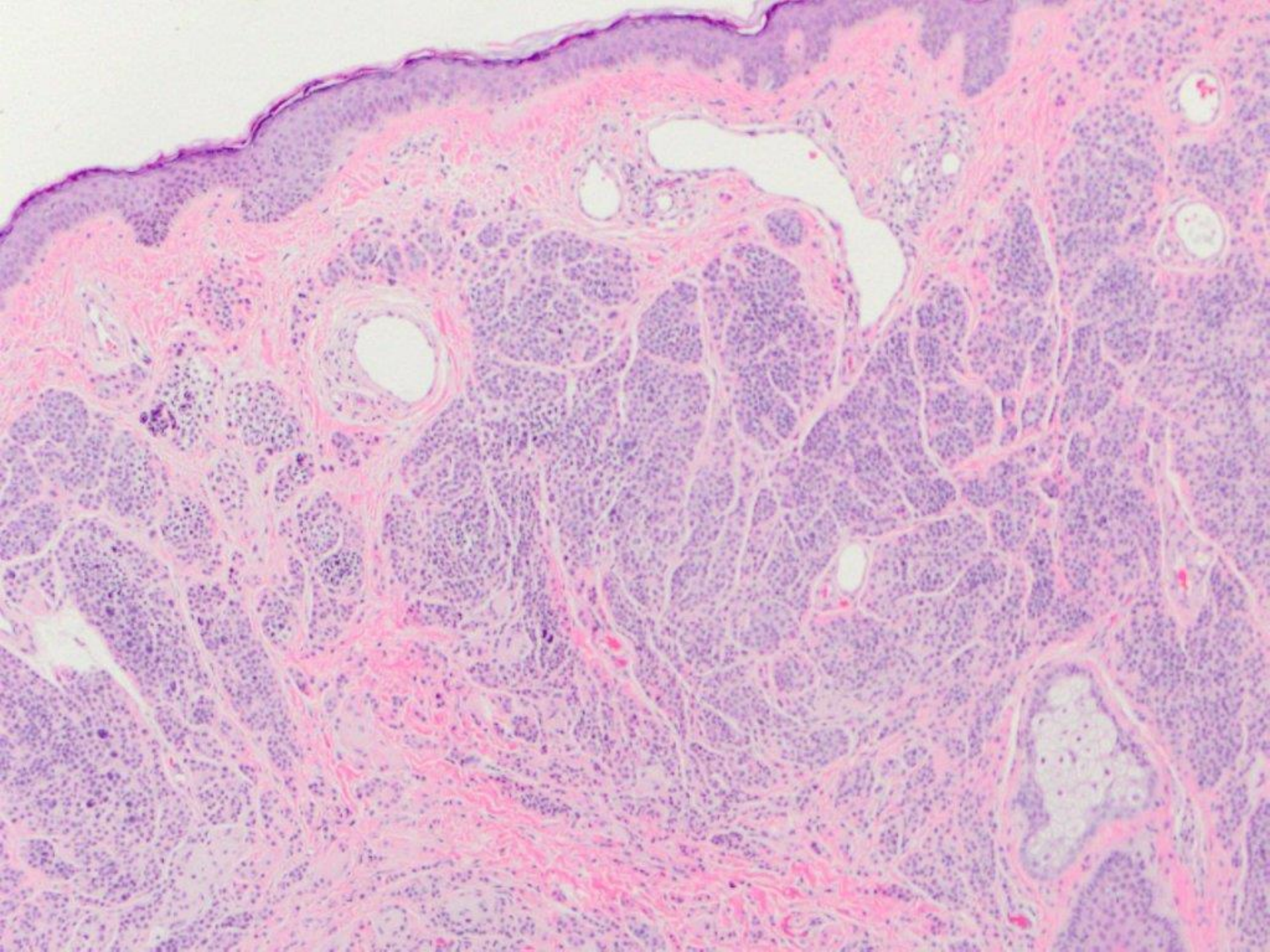


periductal lymphocytic infiltrates, histologically c/w Sjogren Syndrome

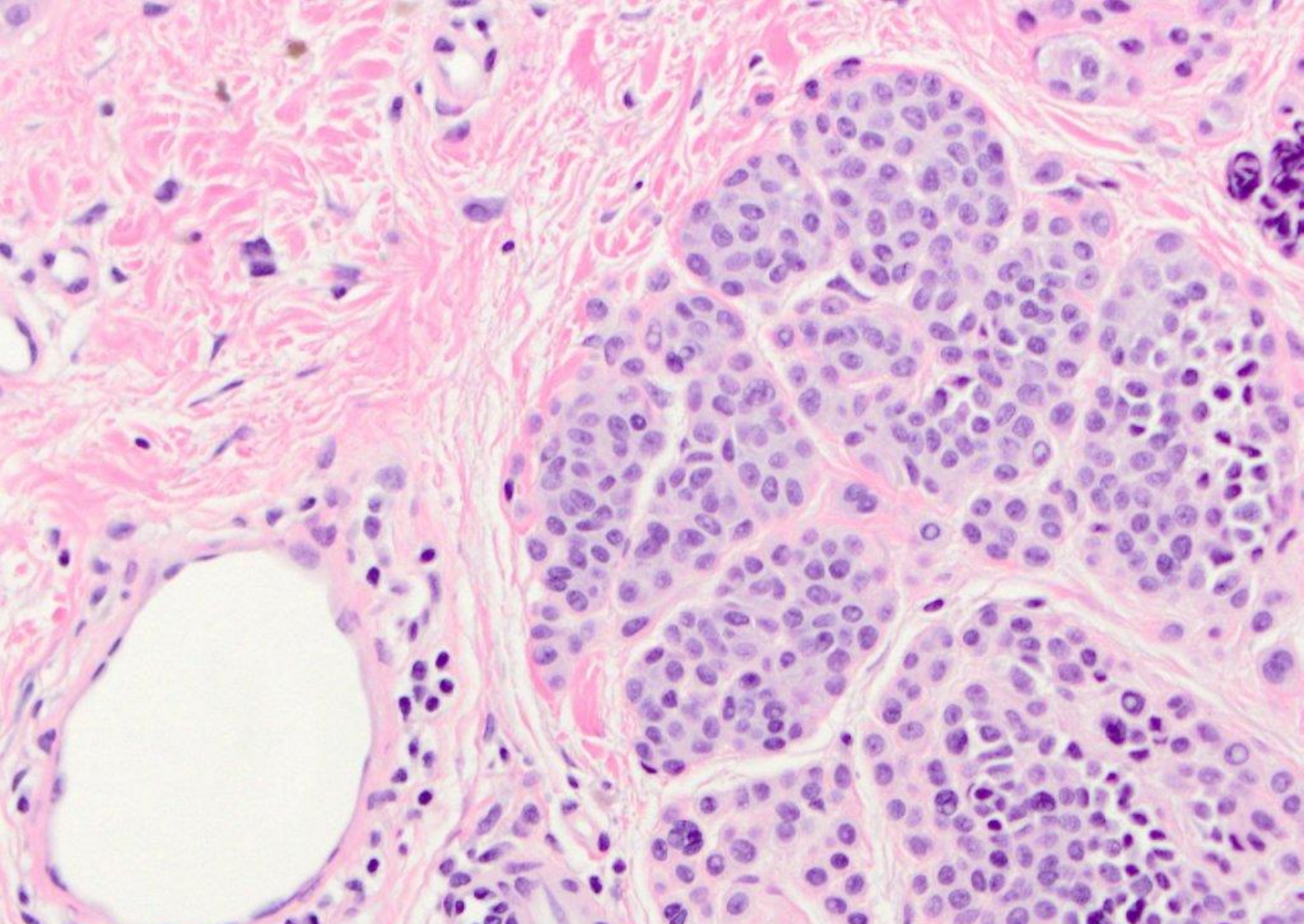






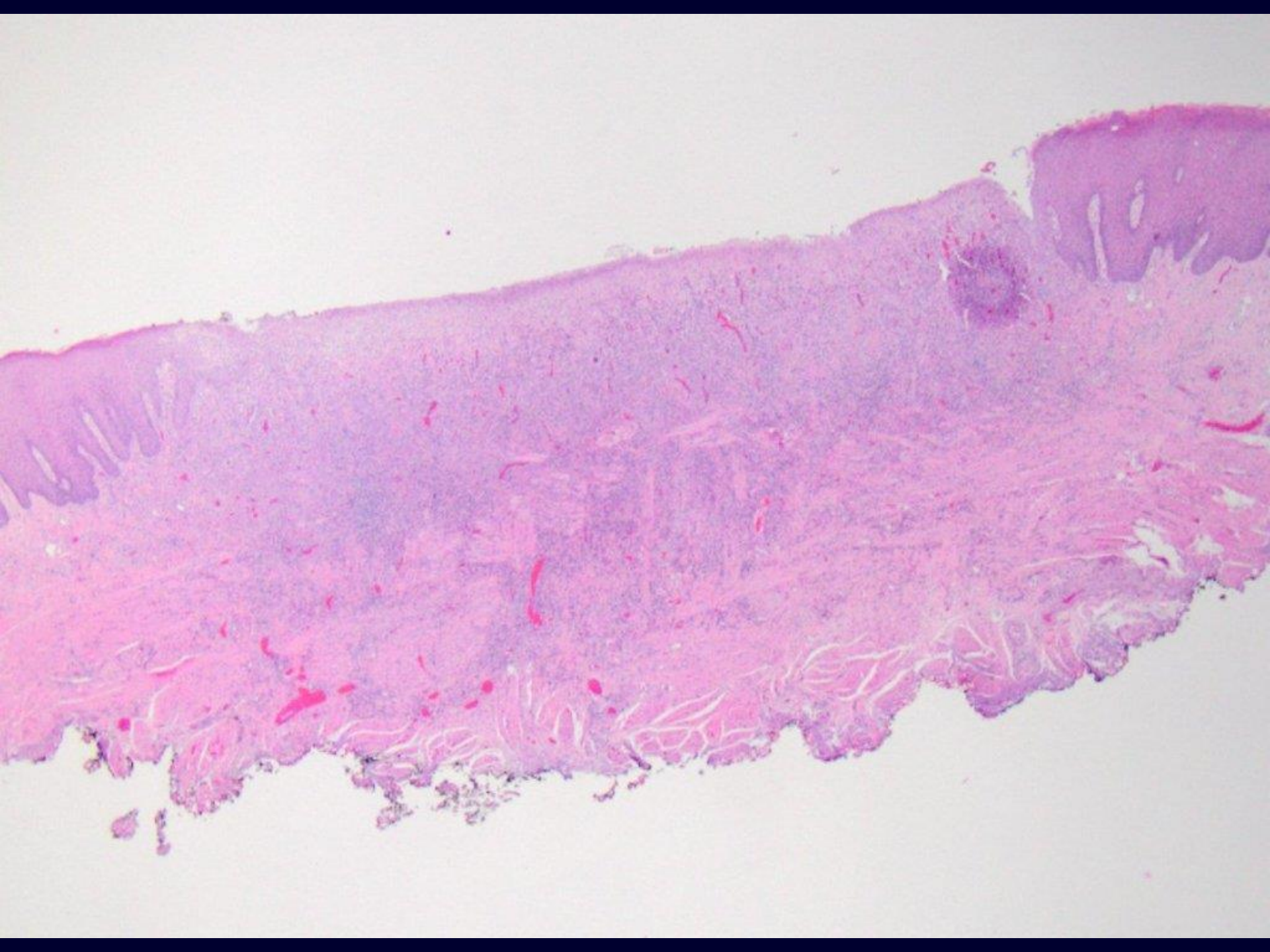




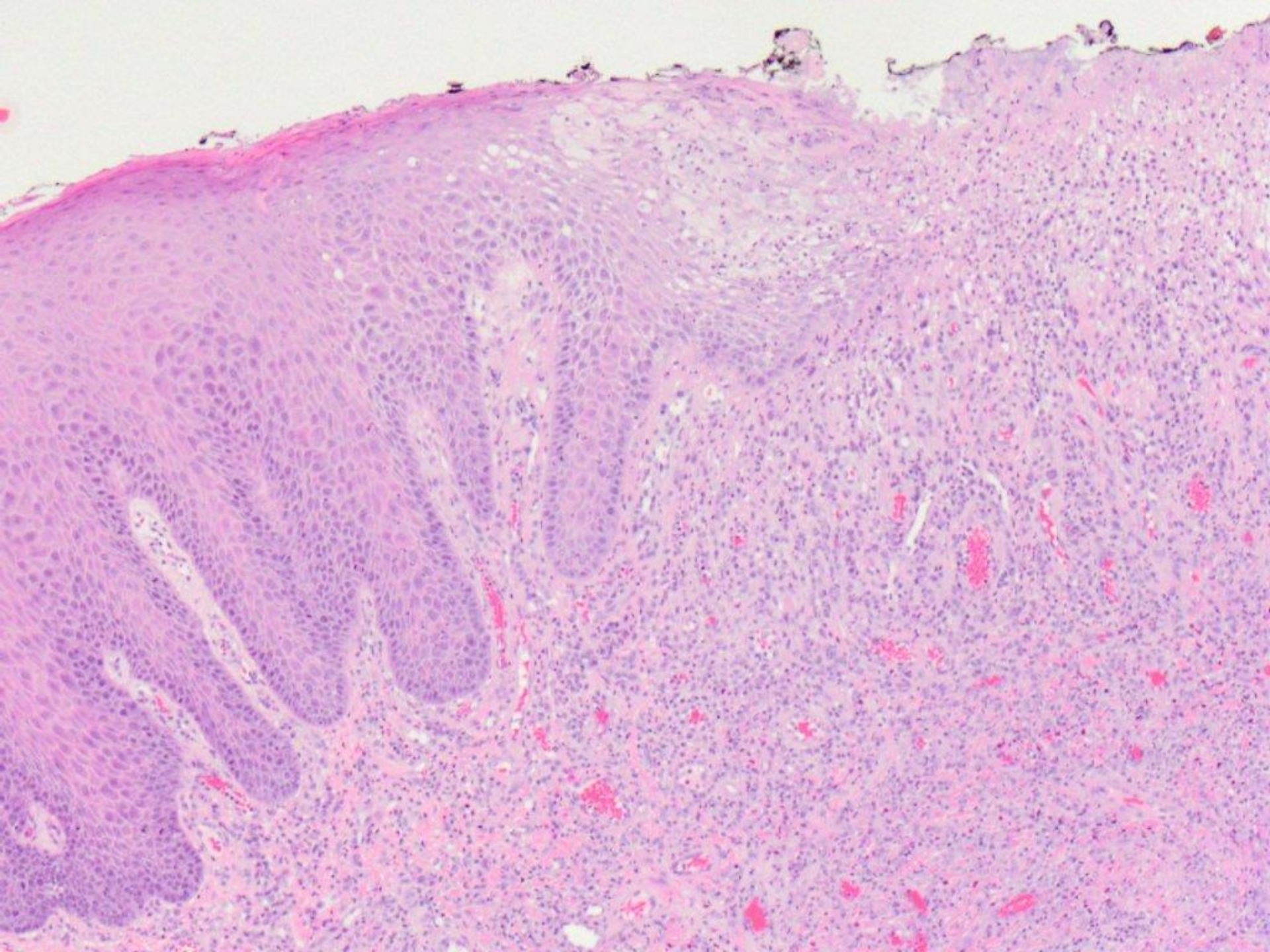


intradermal melanocytic nevus

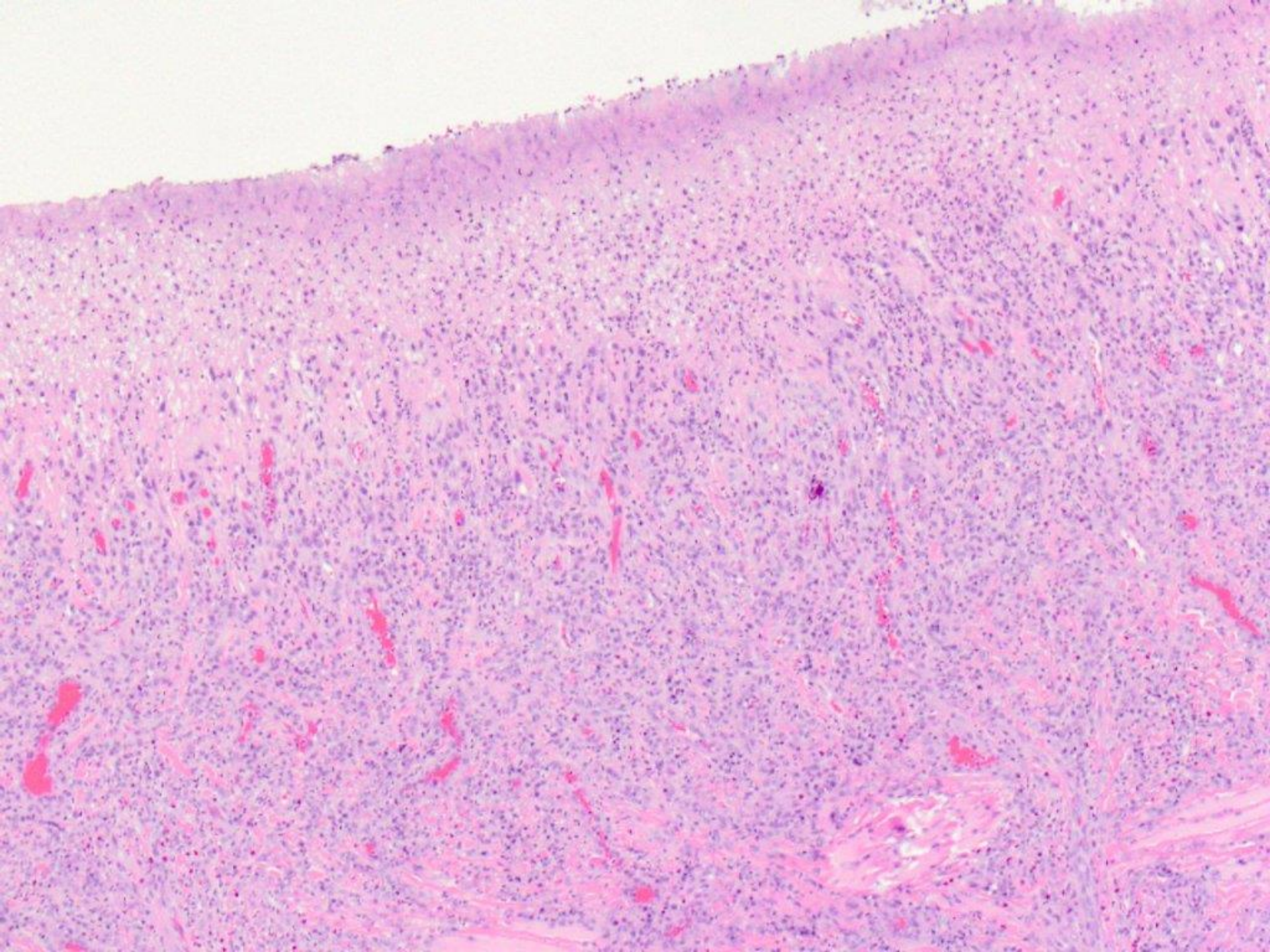




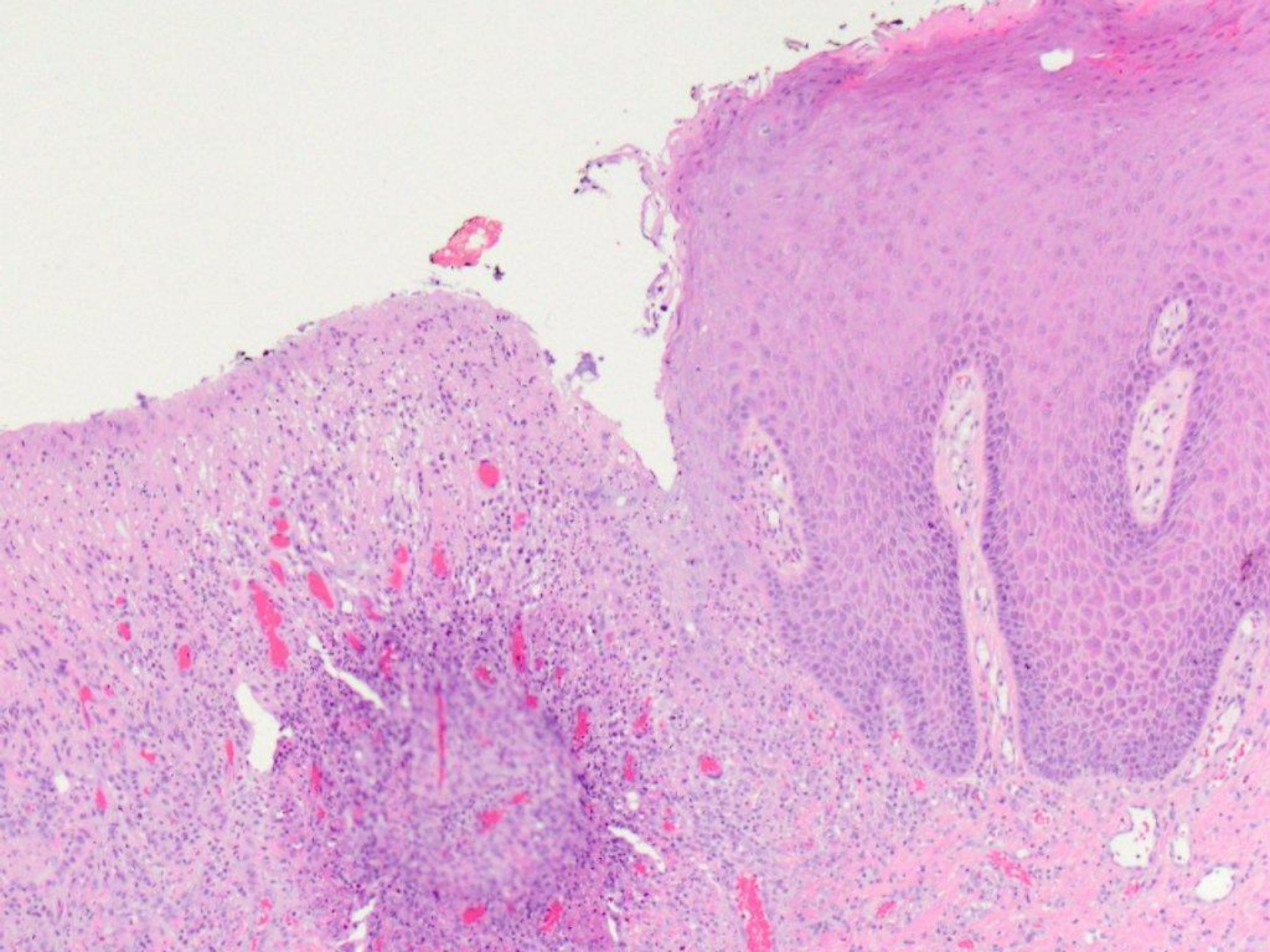




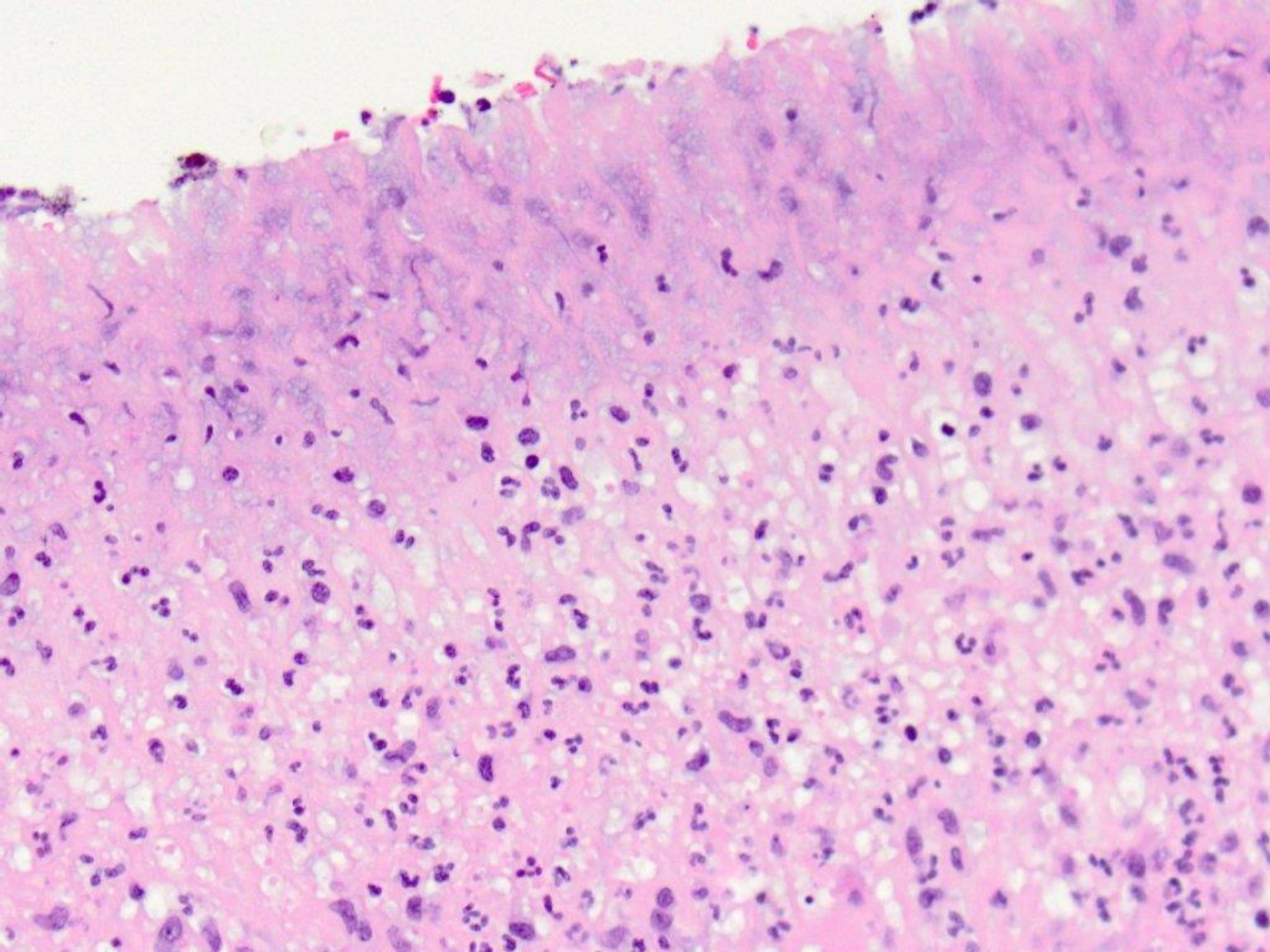




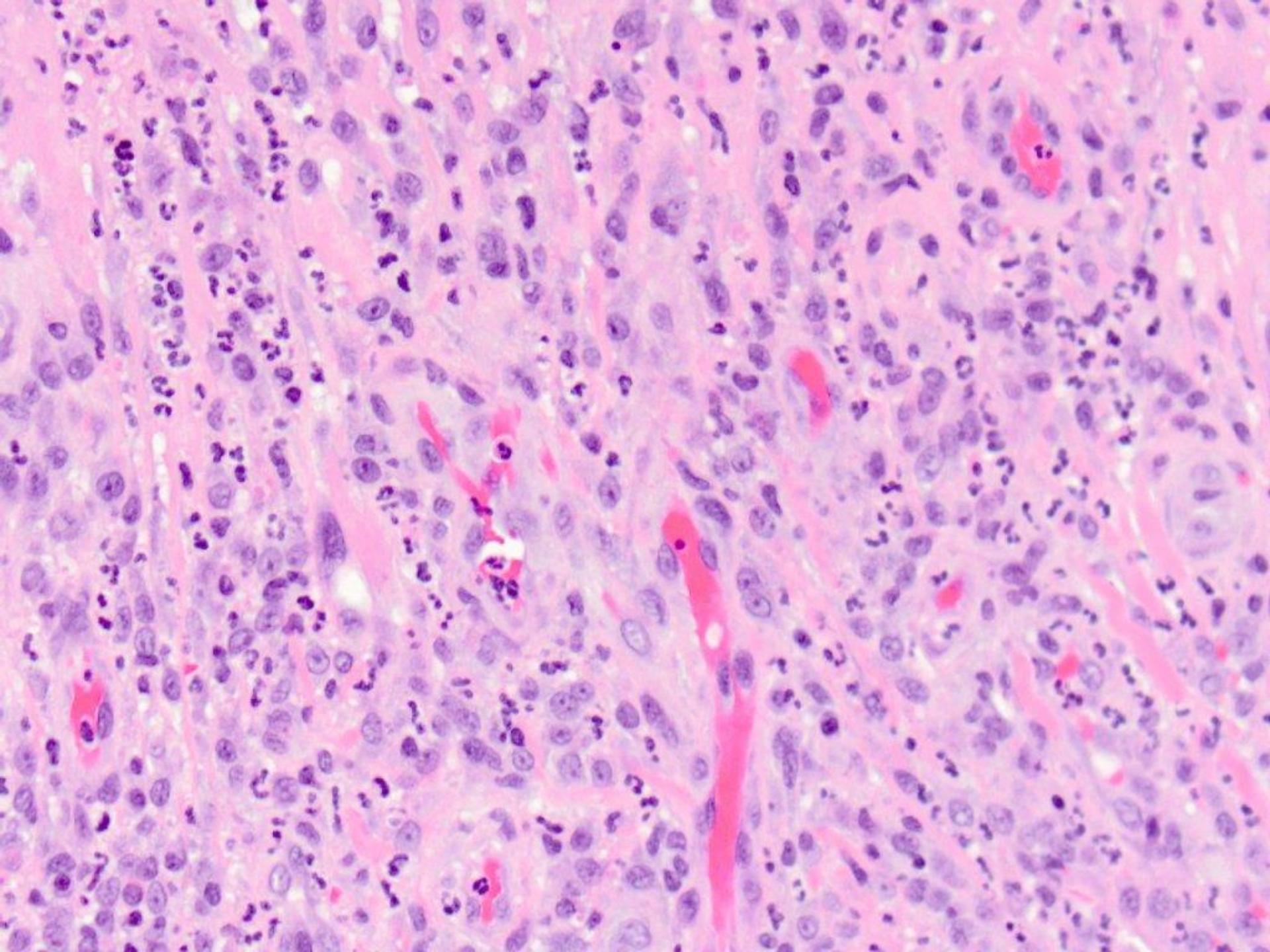




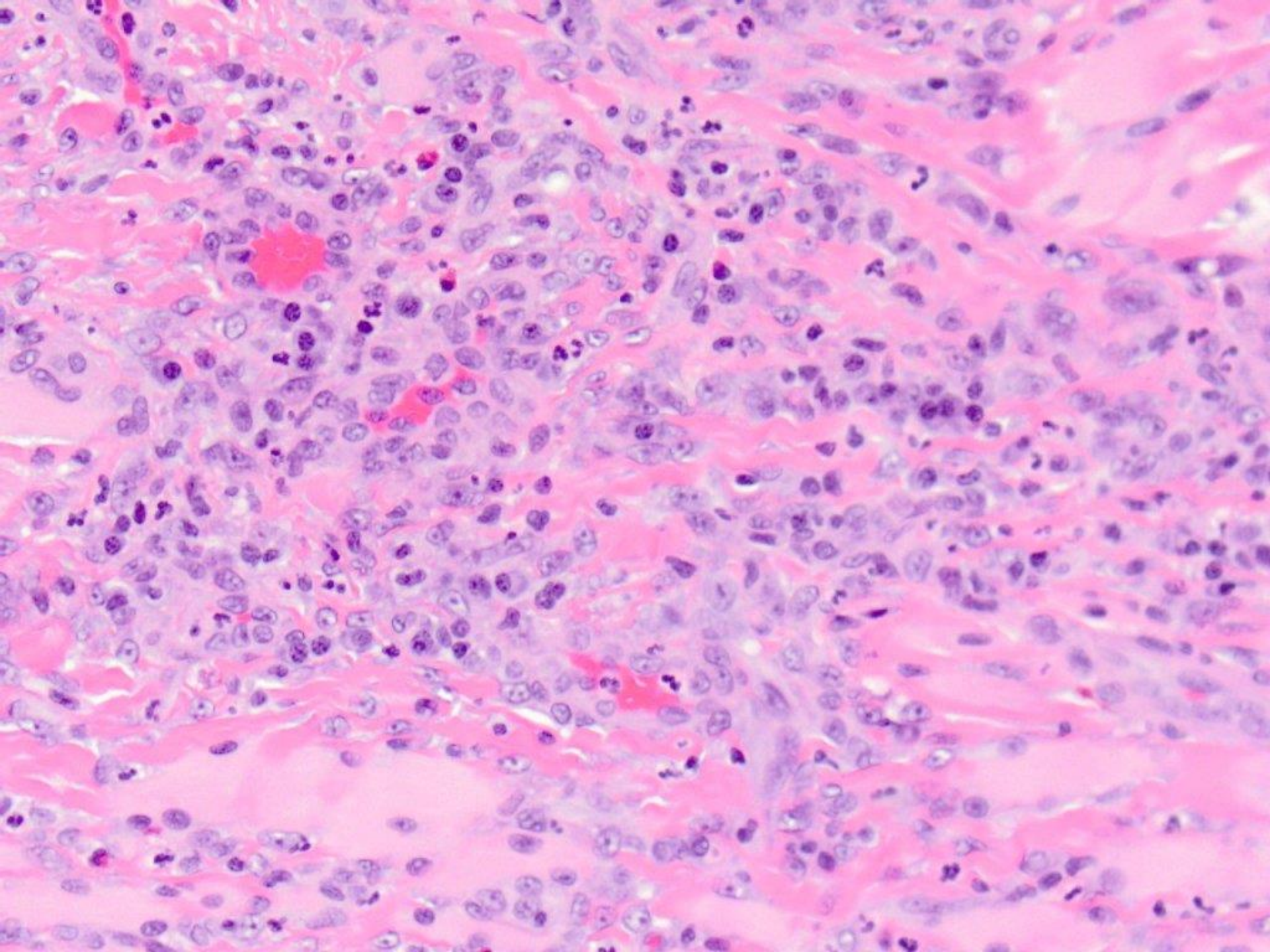




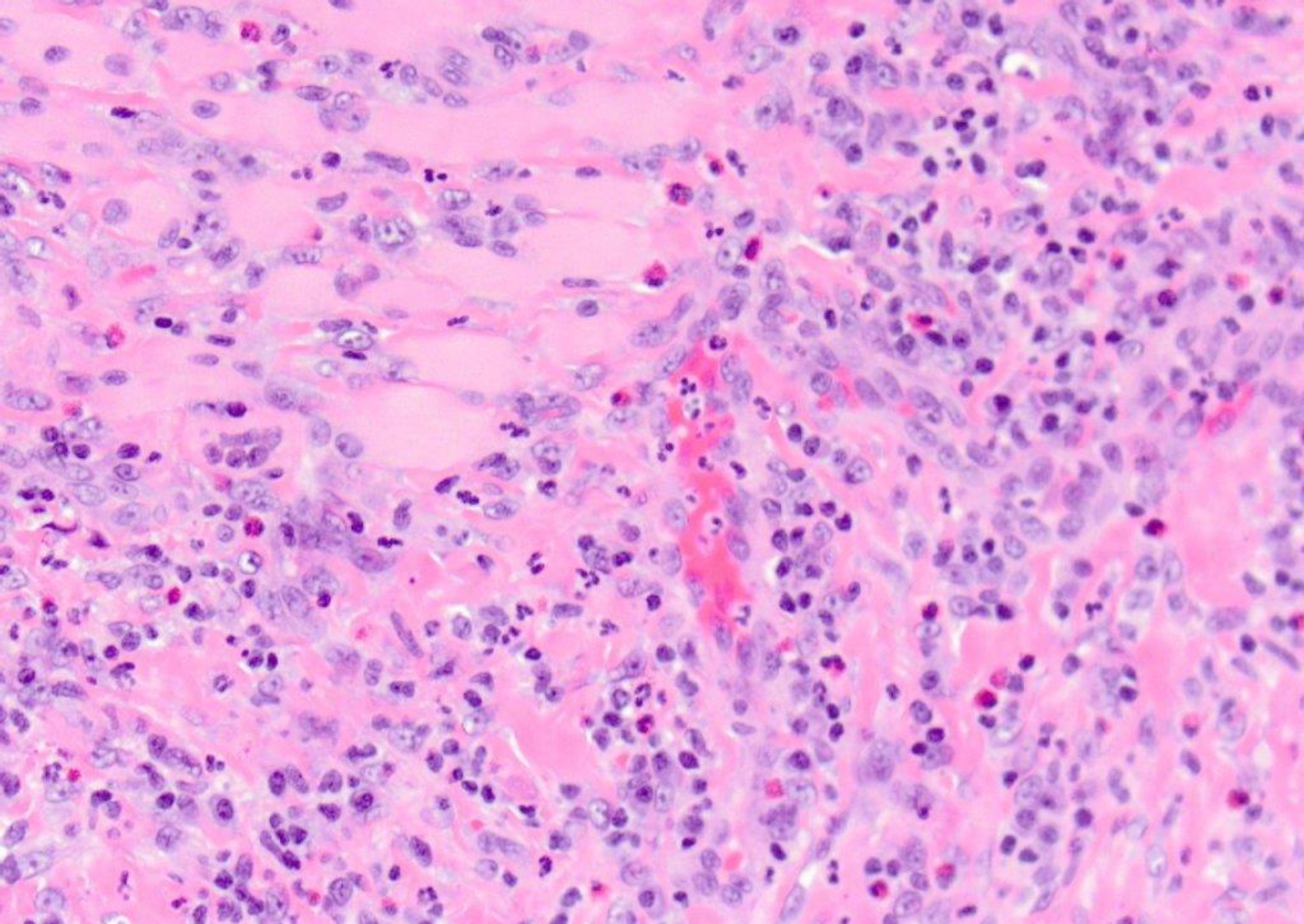






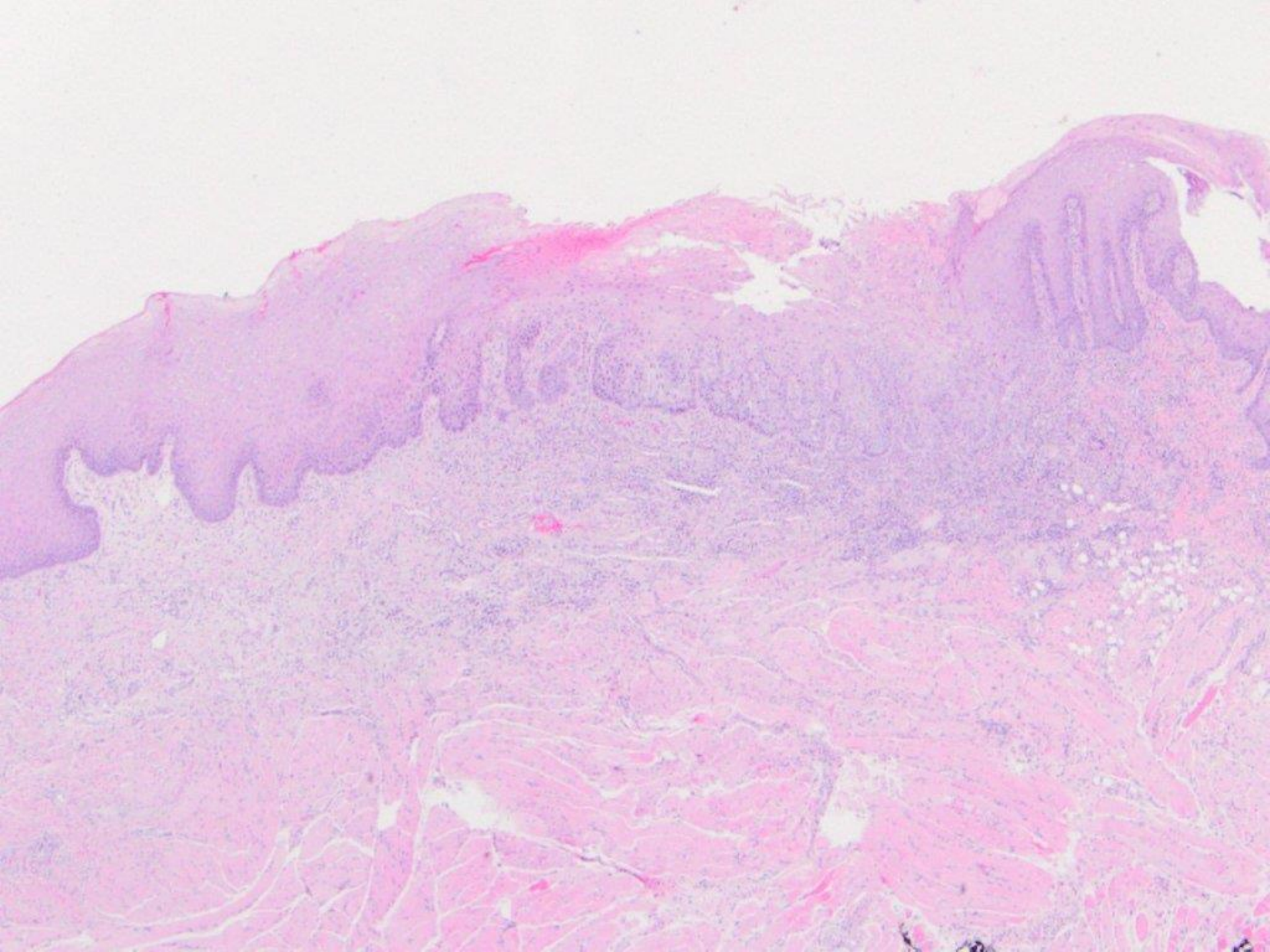




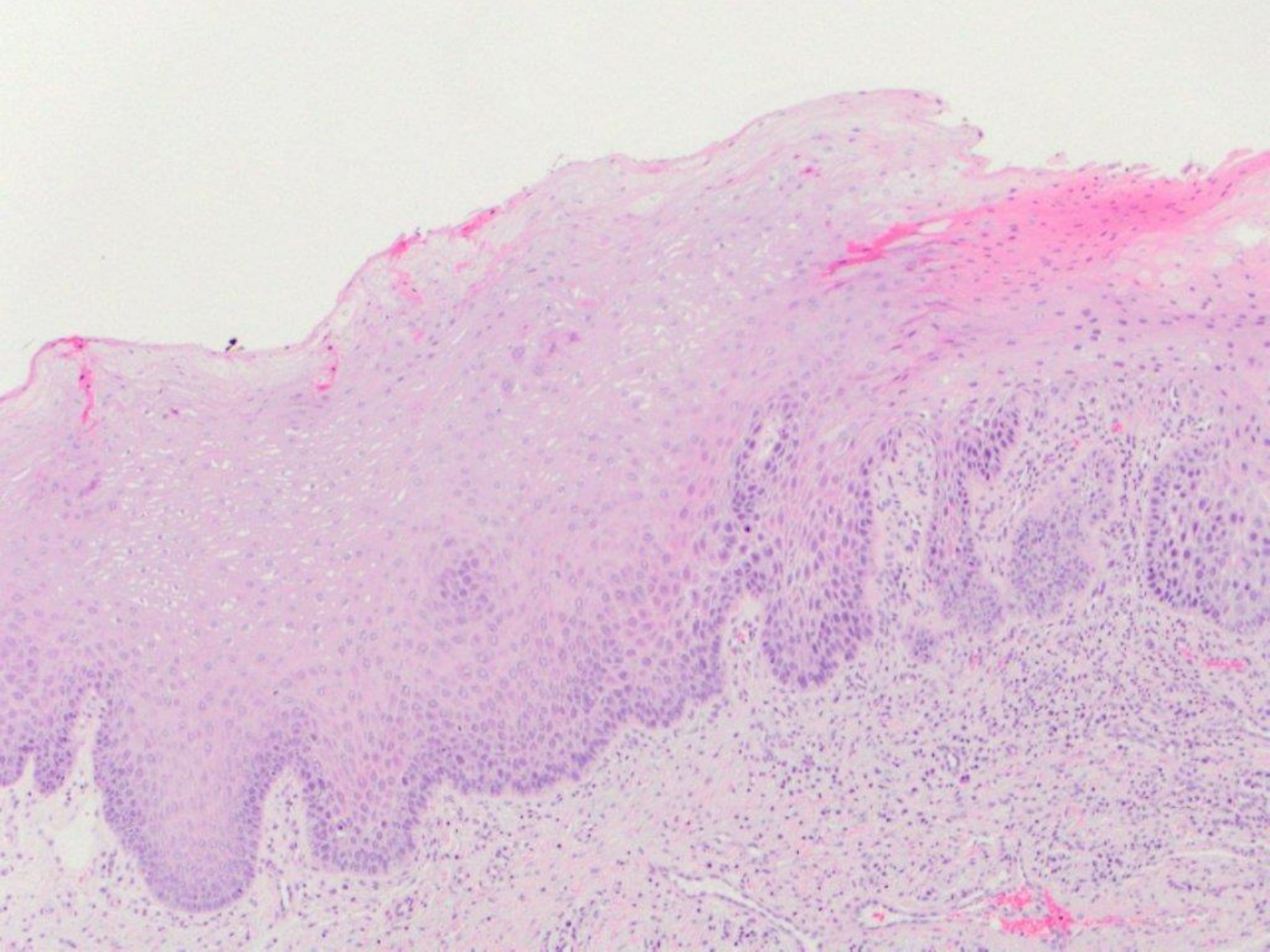


nonspecific ulcer (note the eosinophils and muscle)

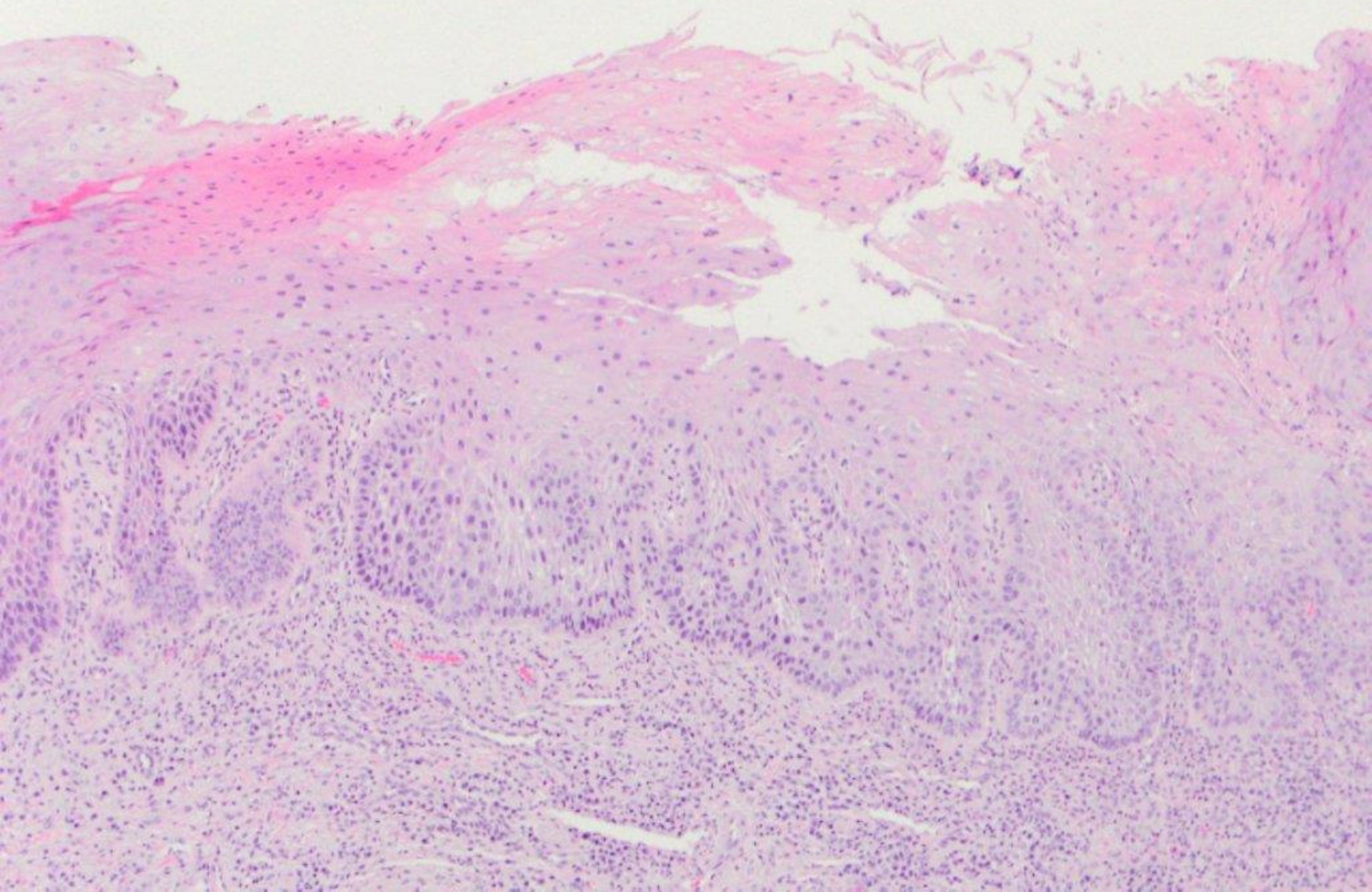




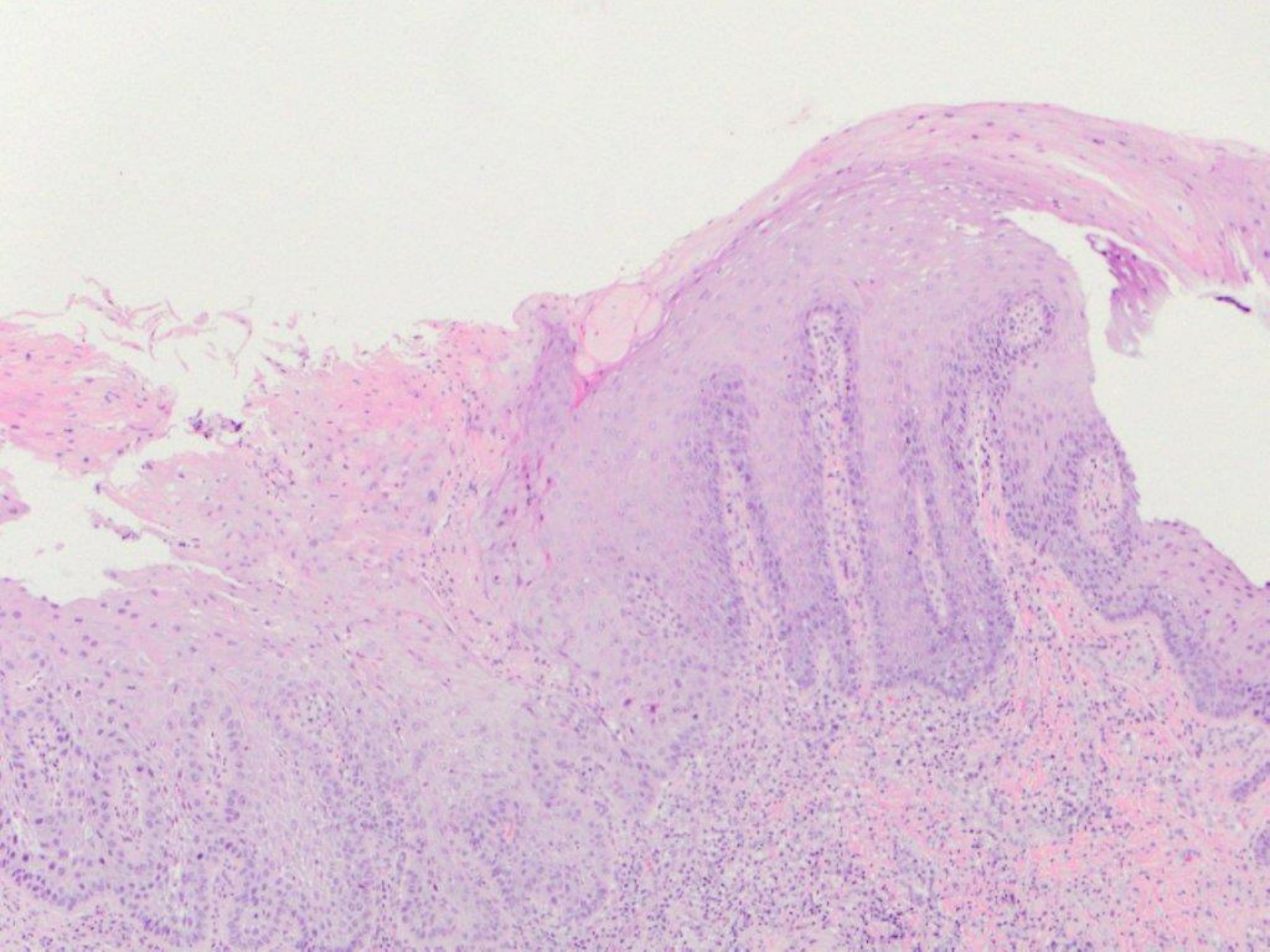




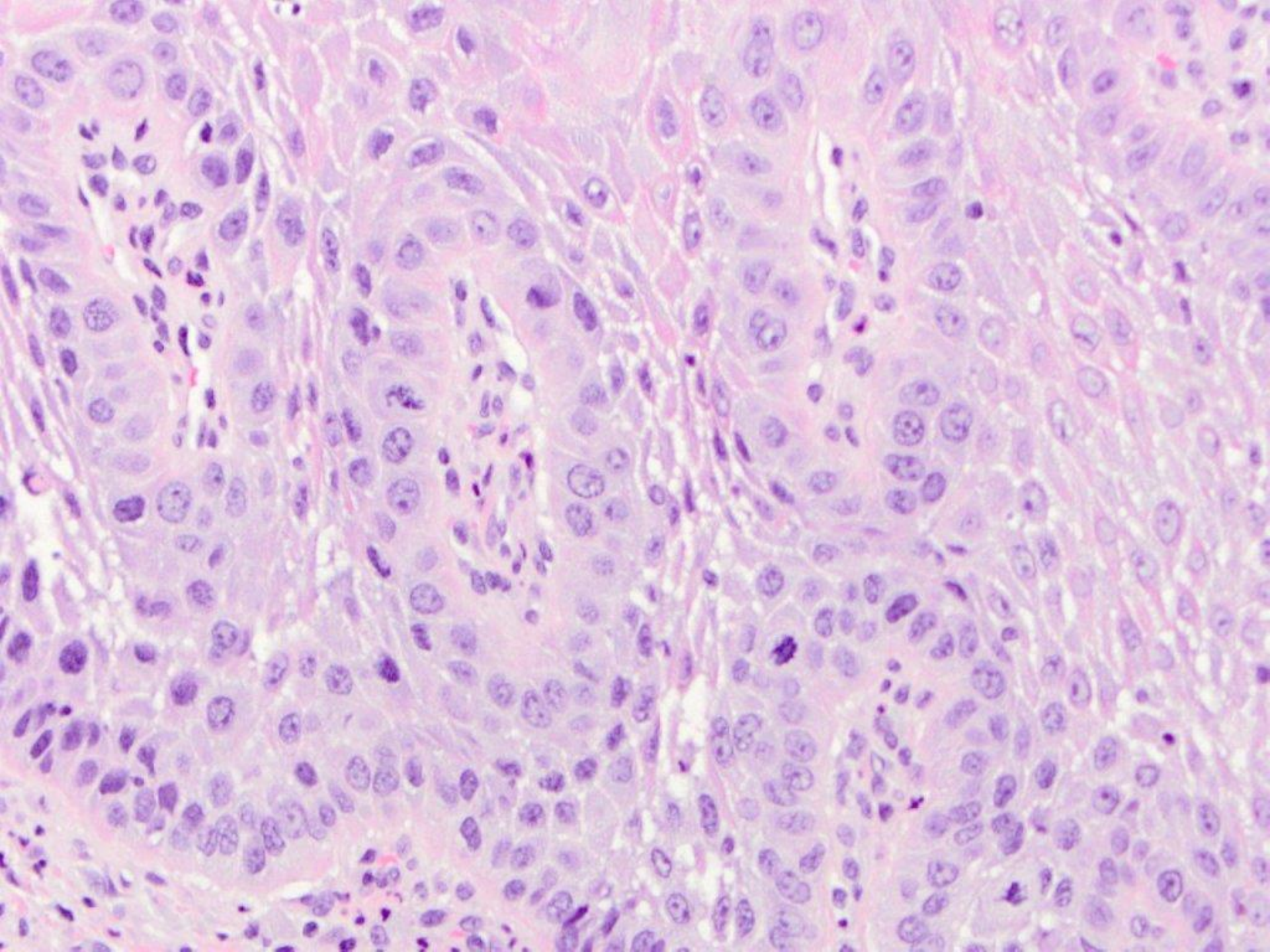




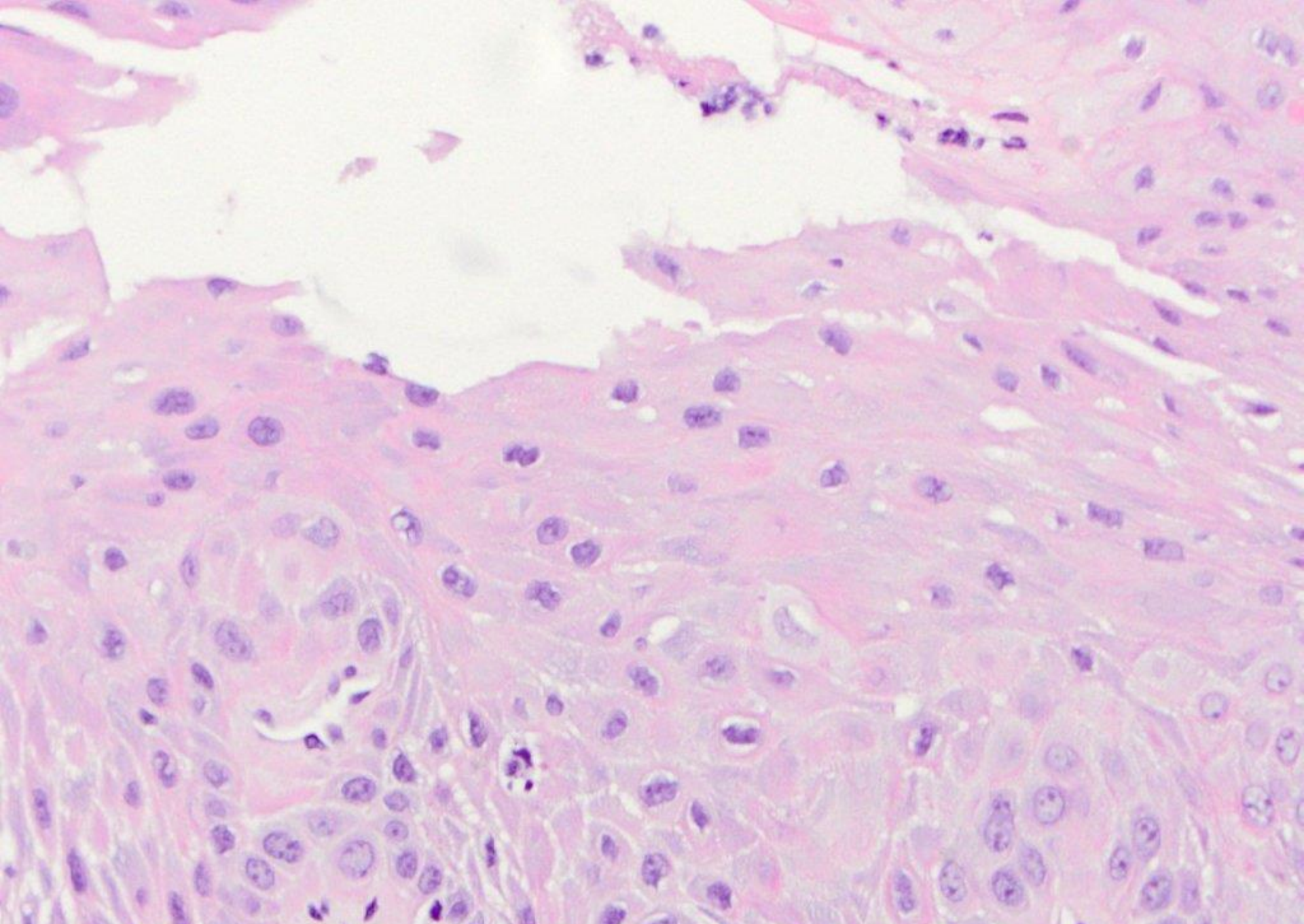






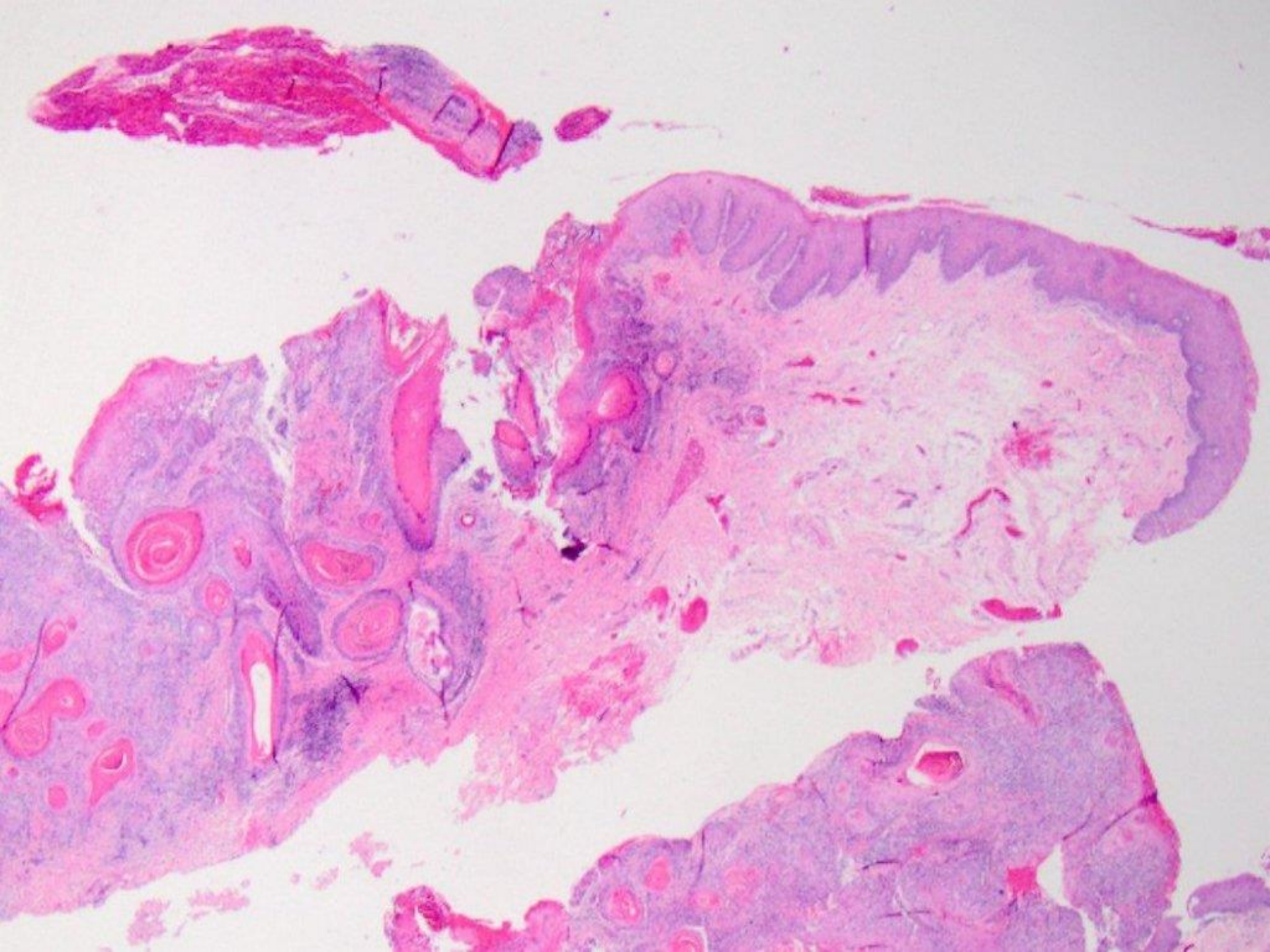




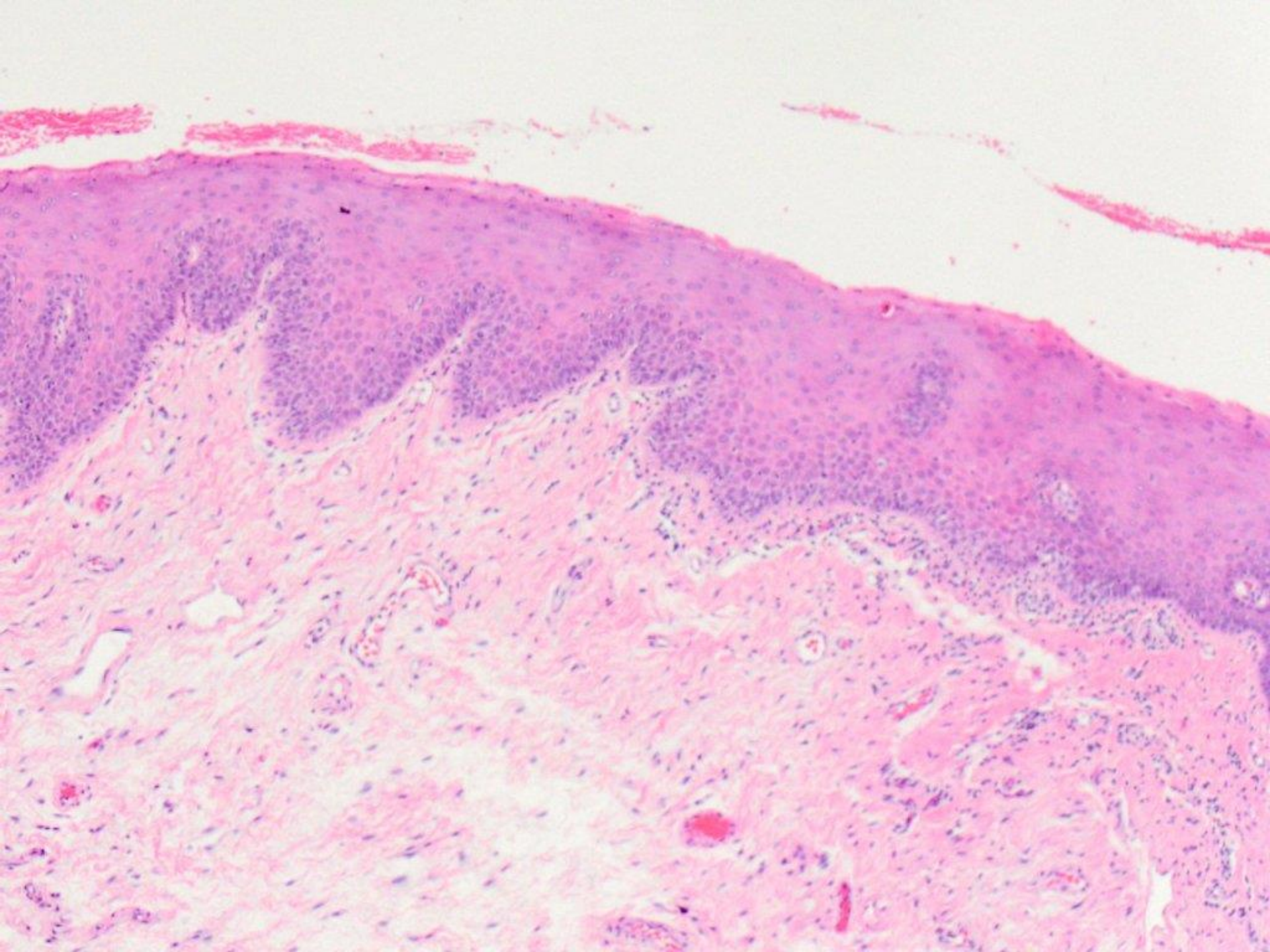


mild to moderate epithelial dysplasia

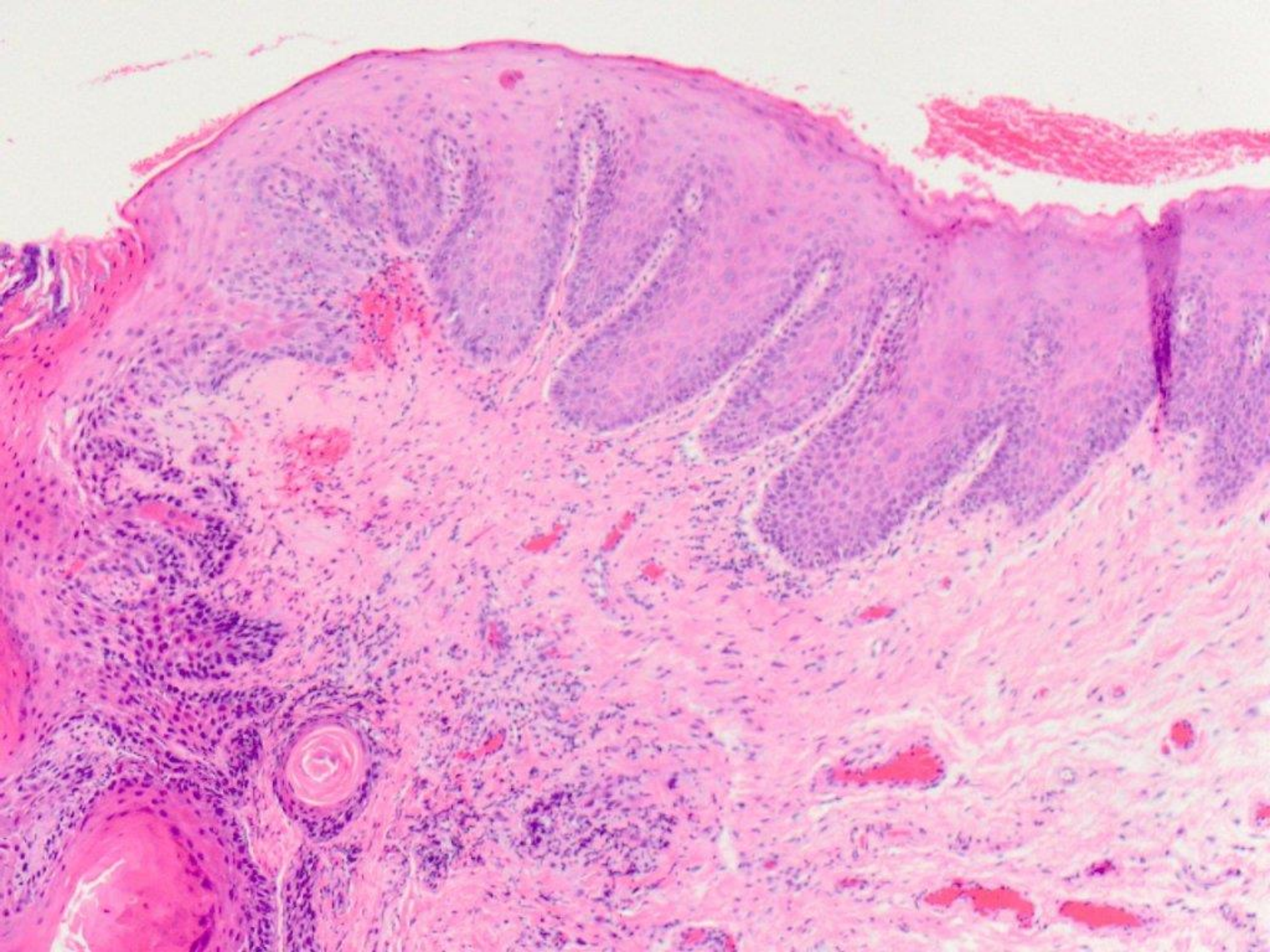




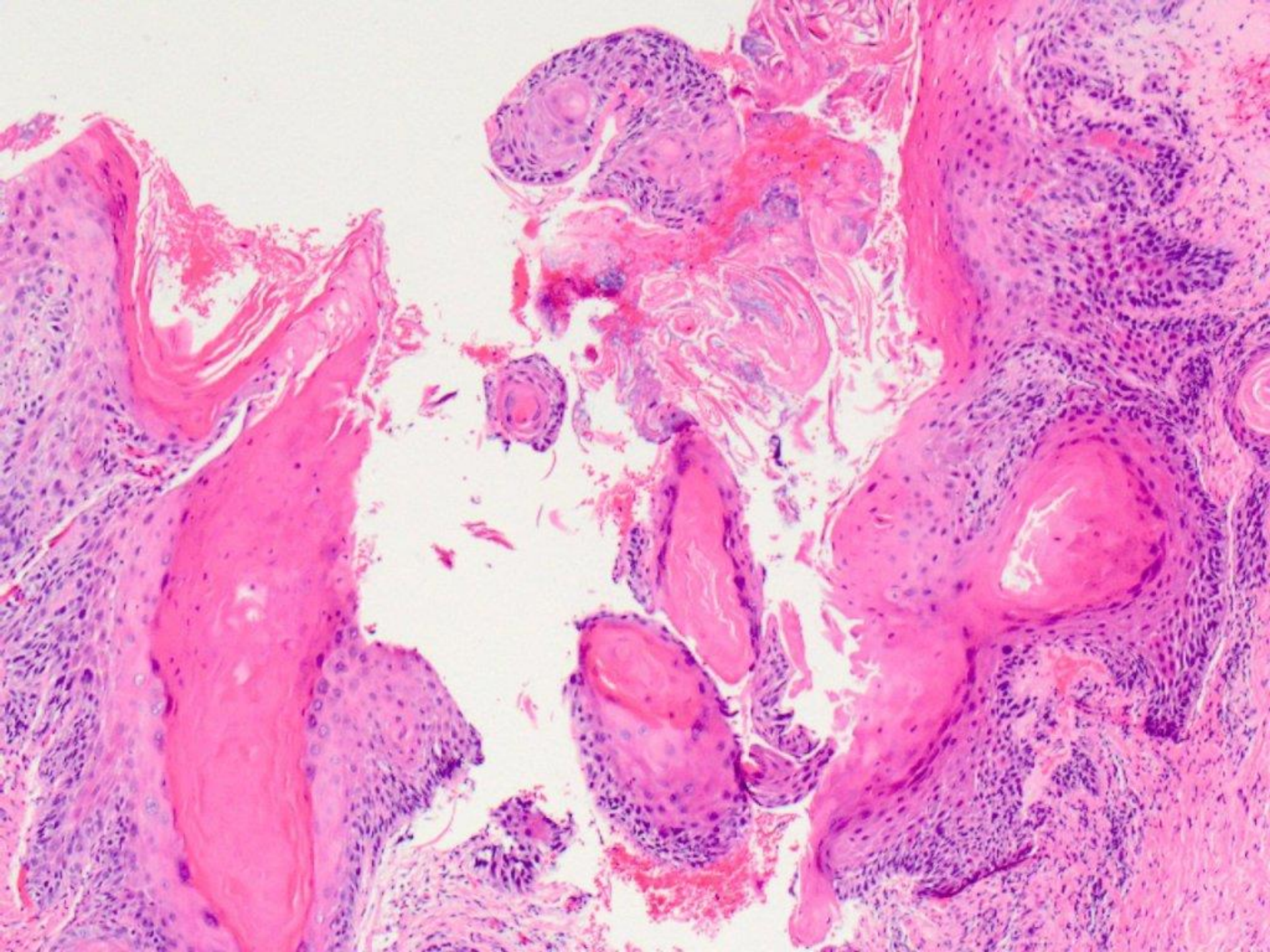




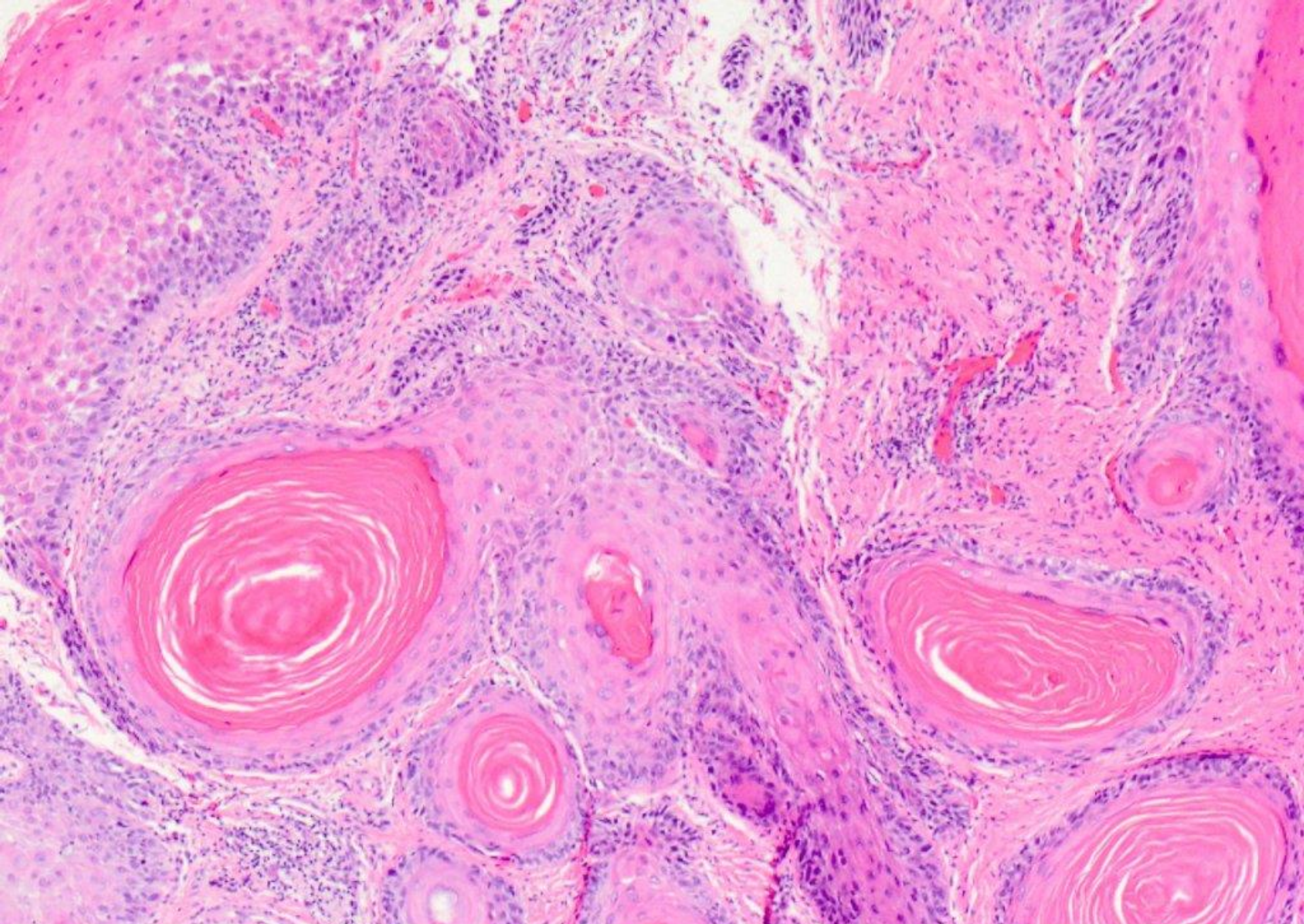






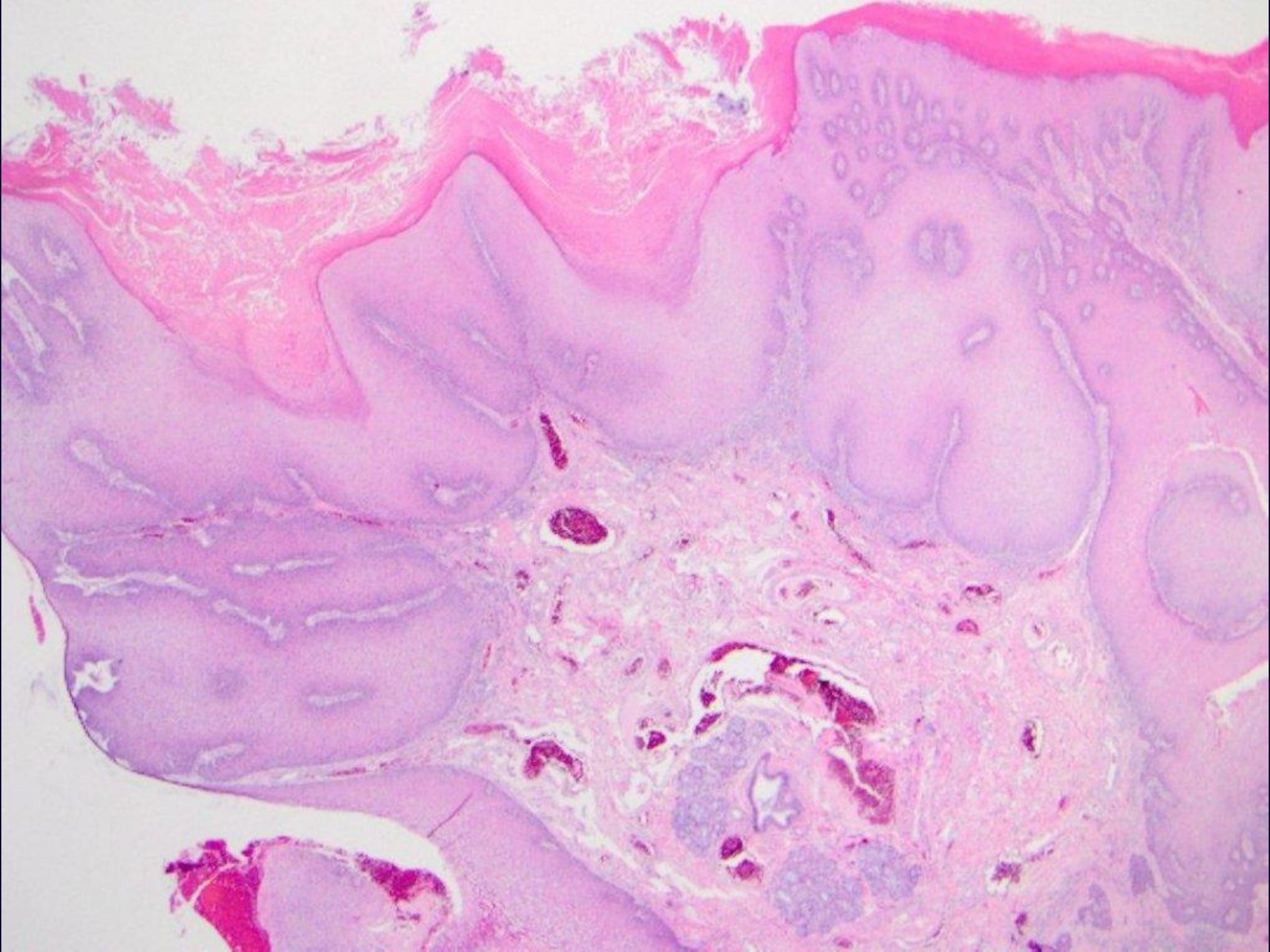




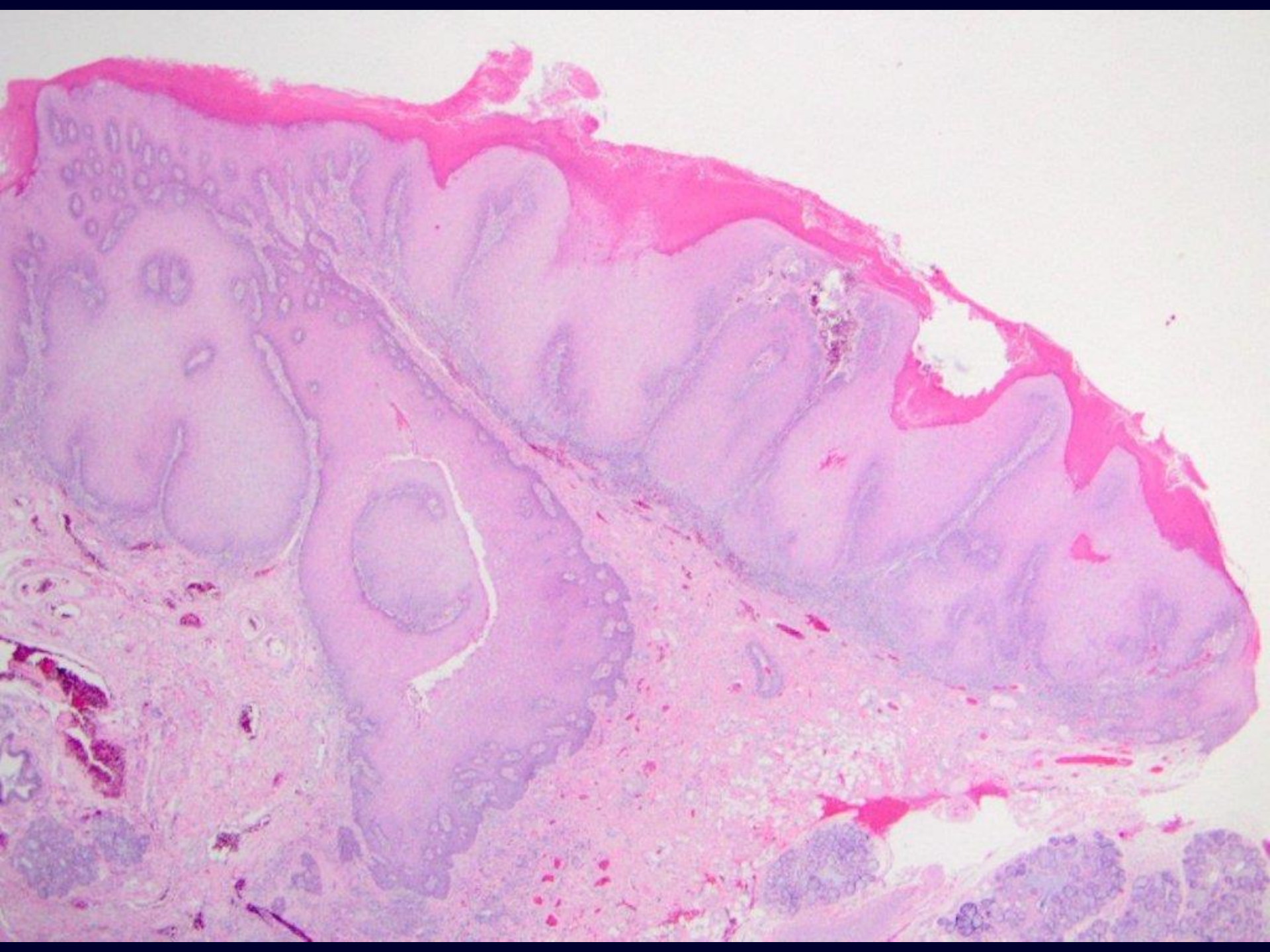


squamous cell carcinoma, well differentiated

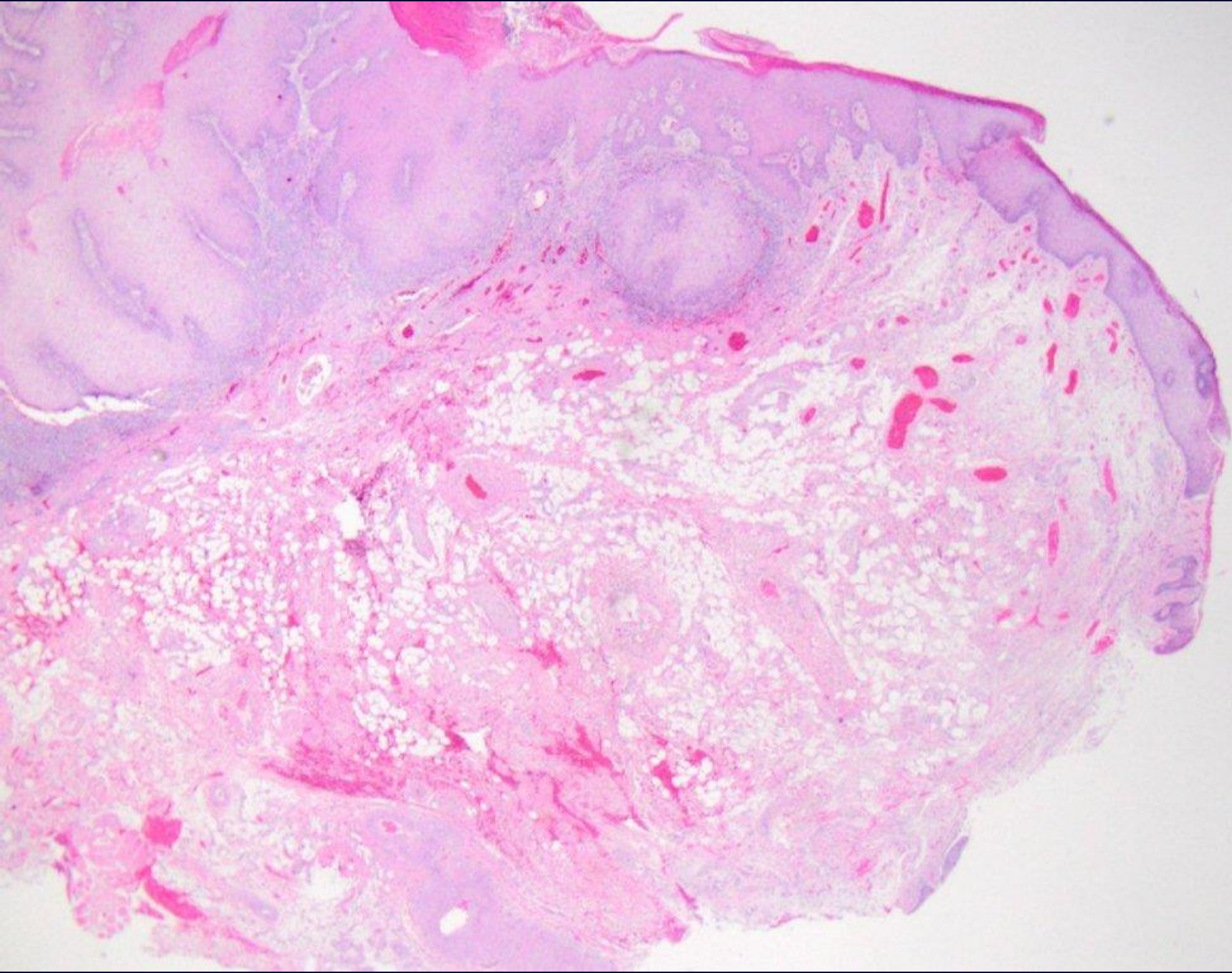




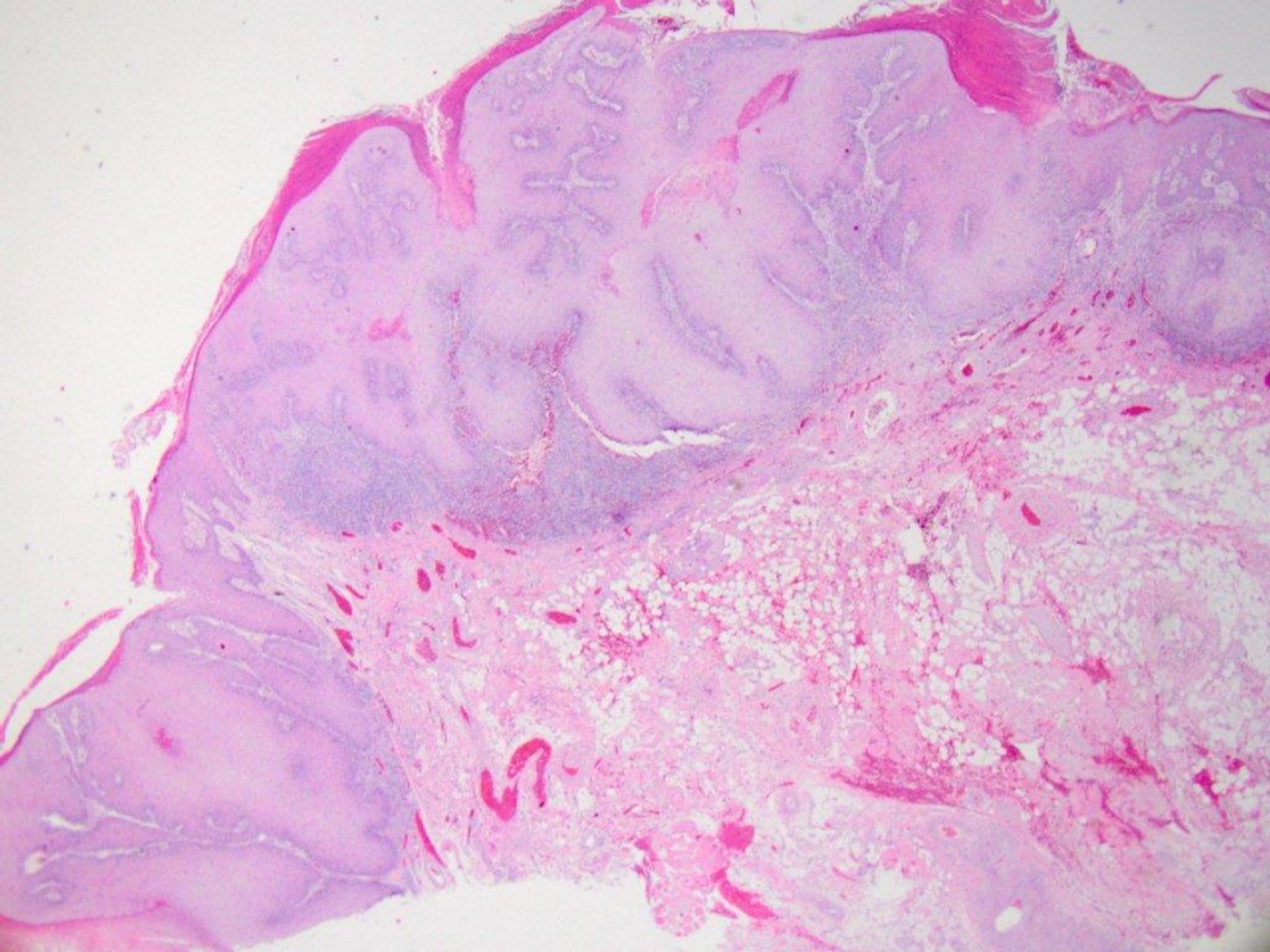




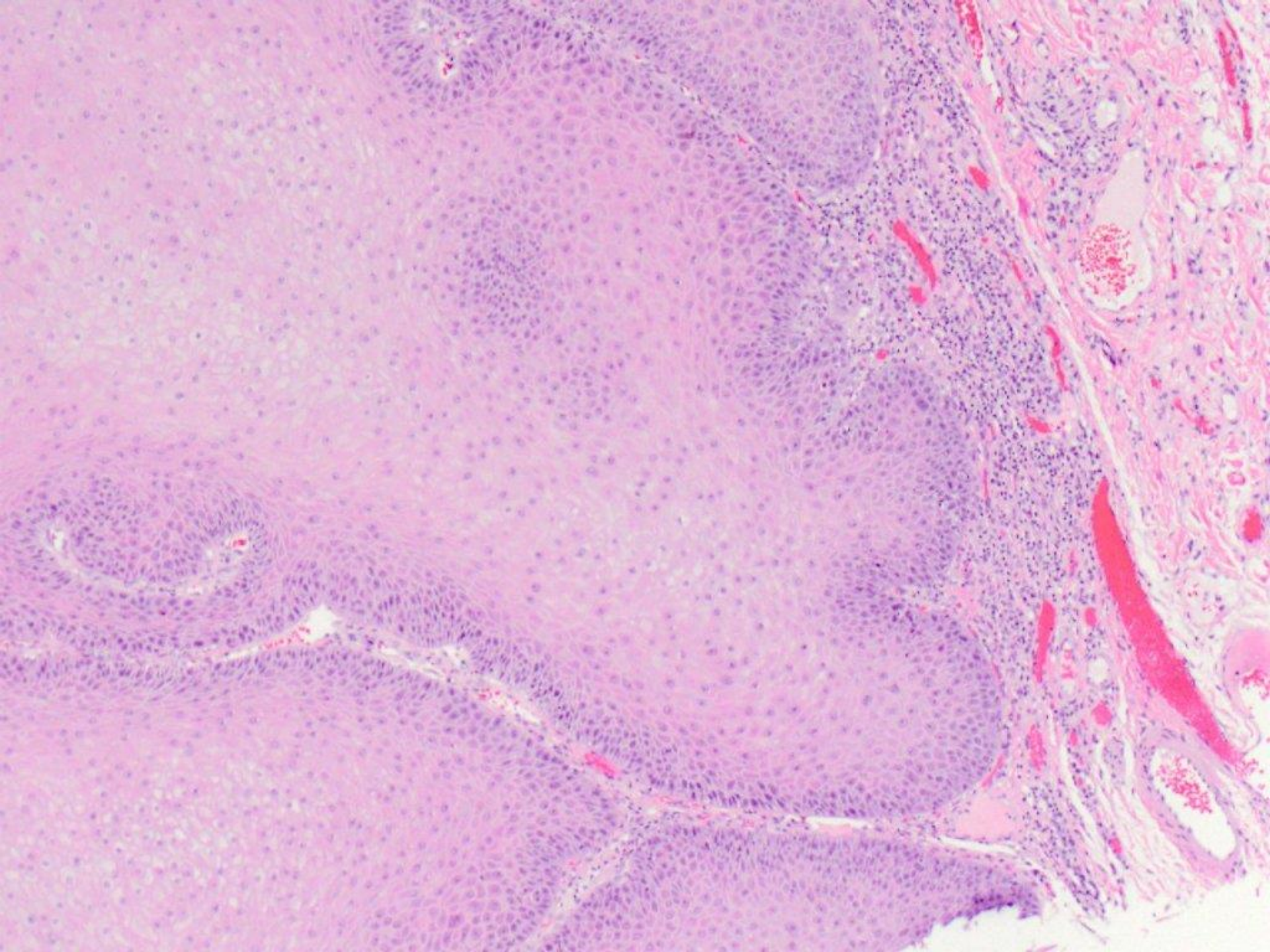




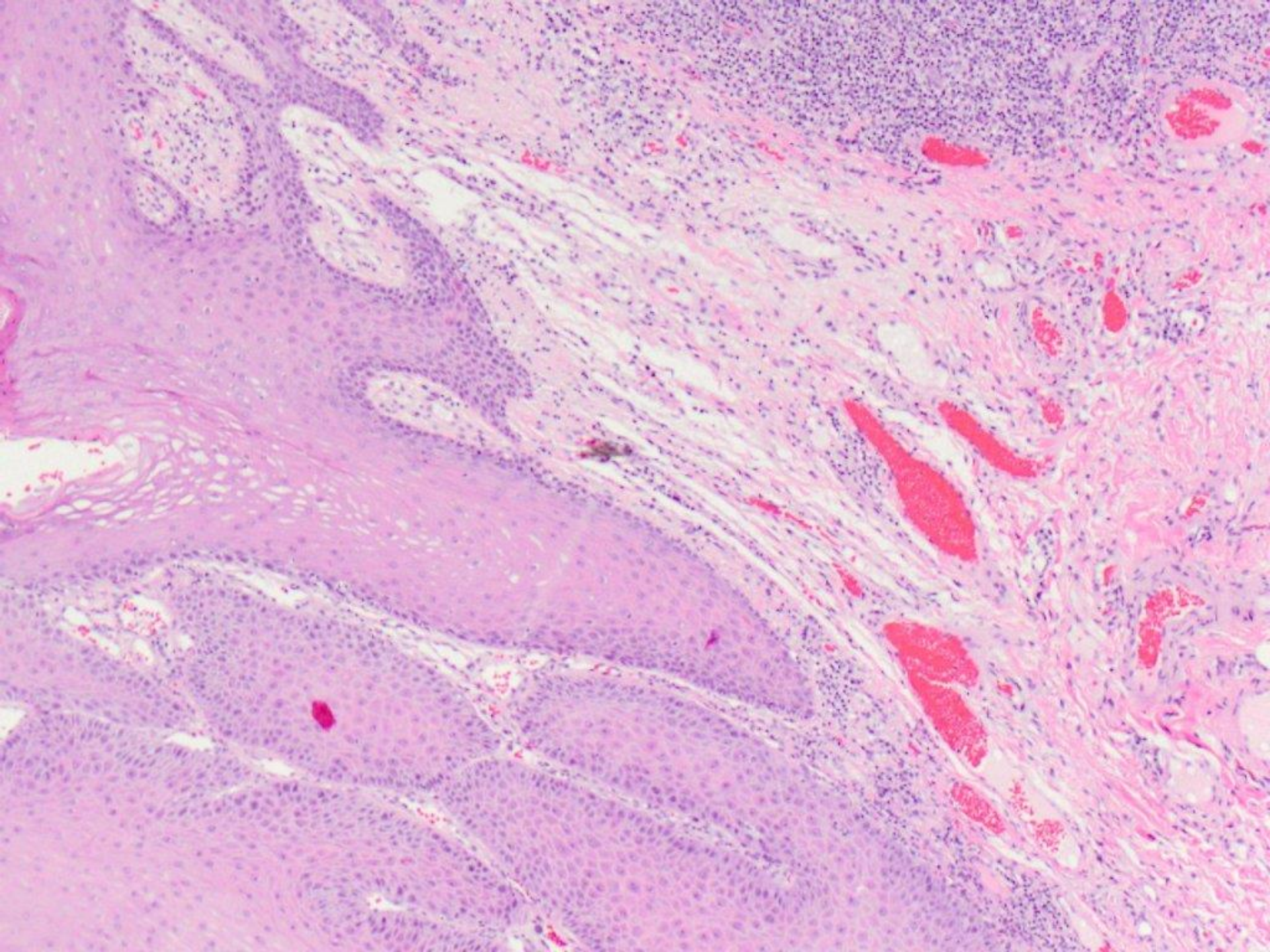




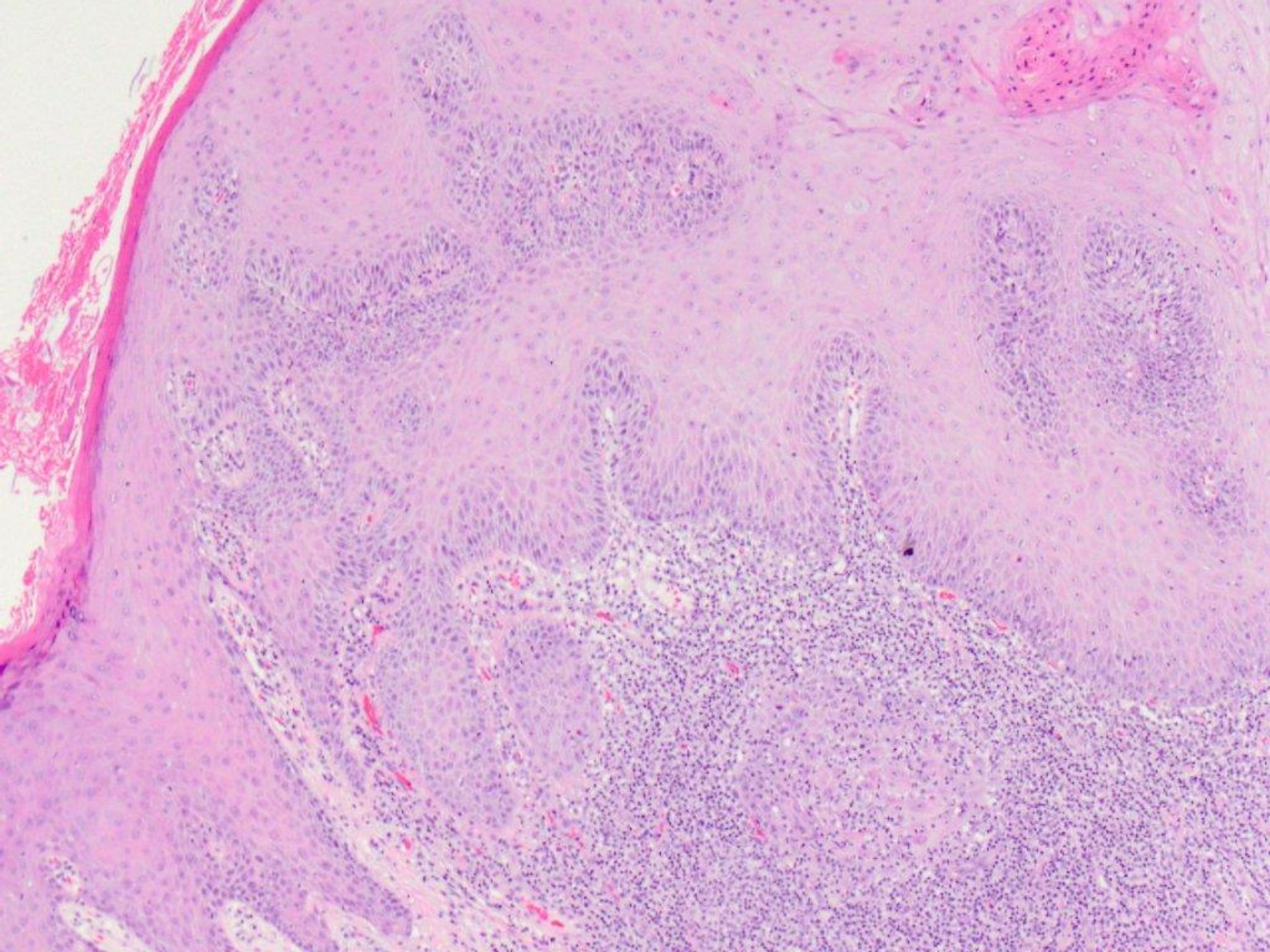




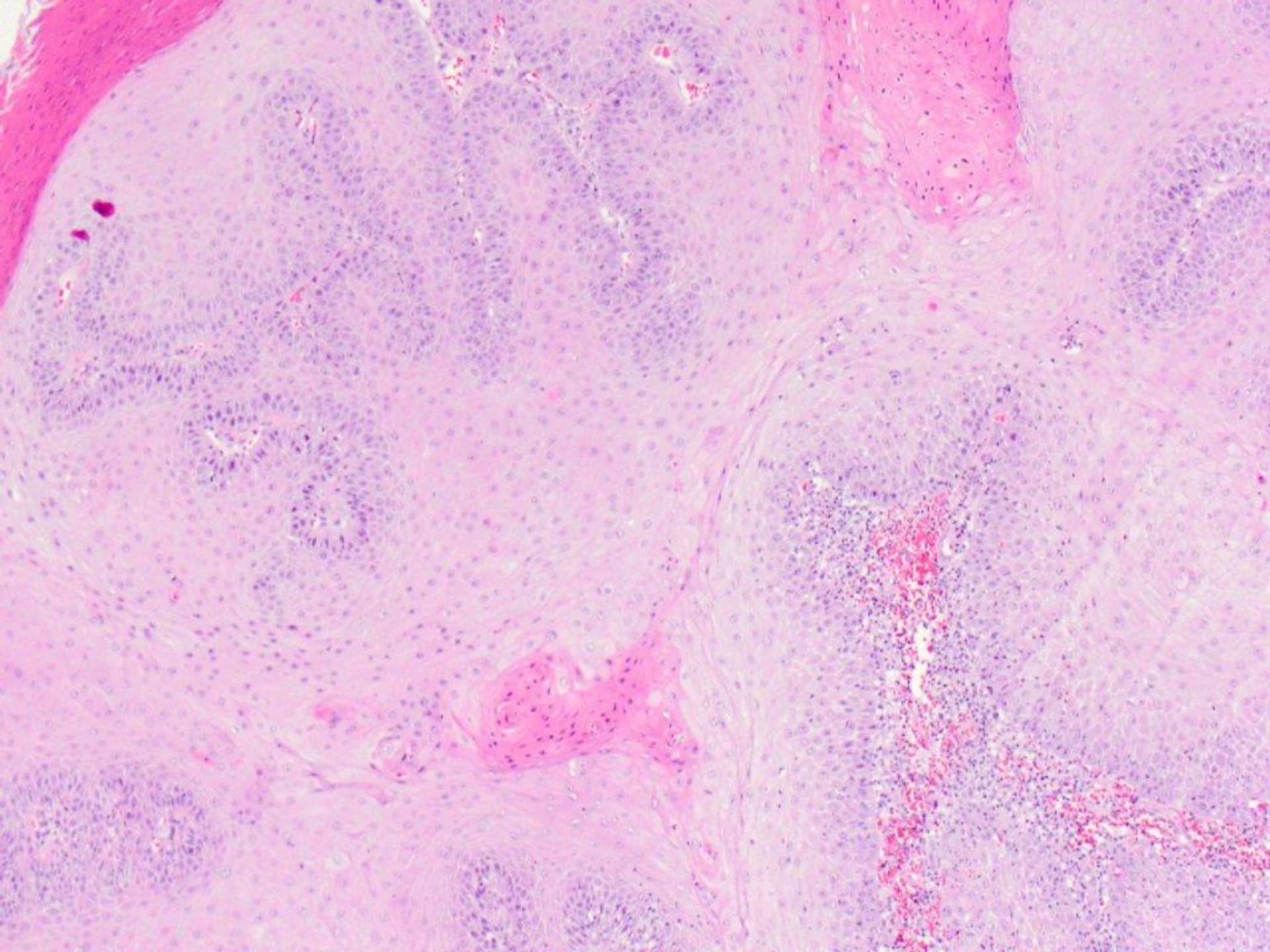




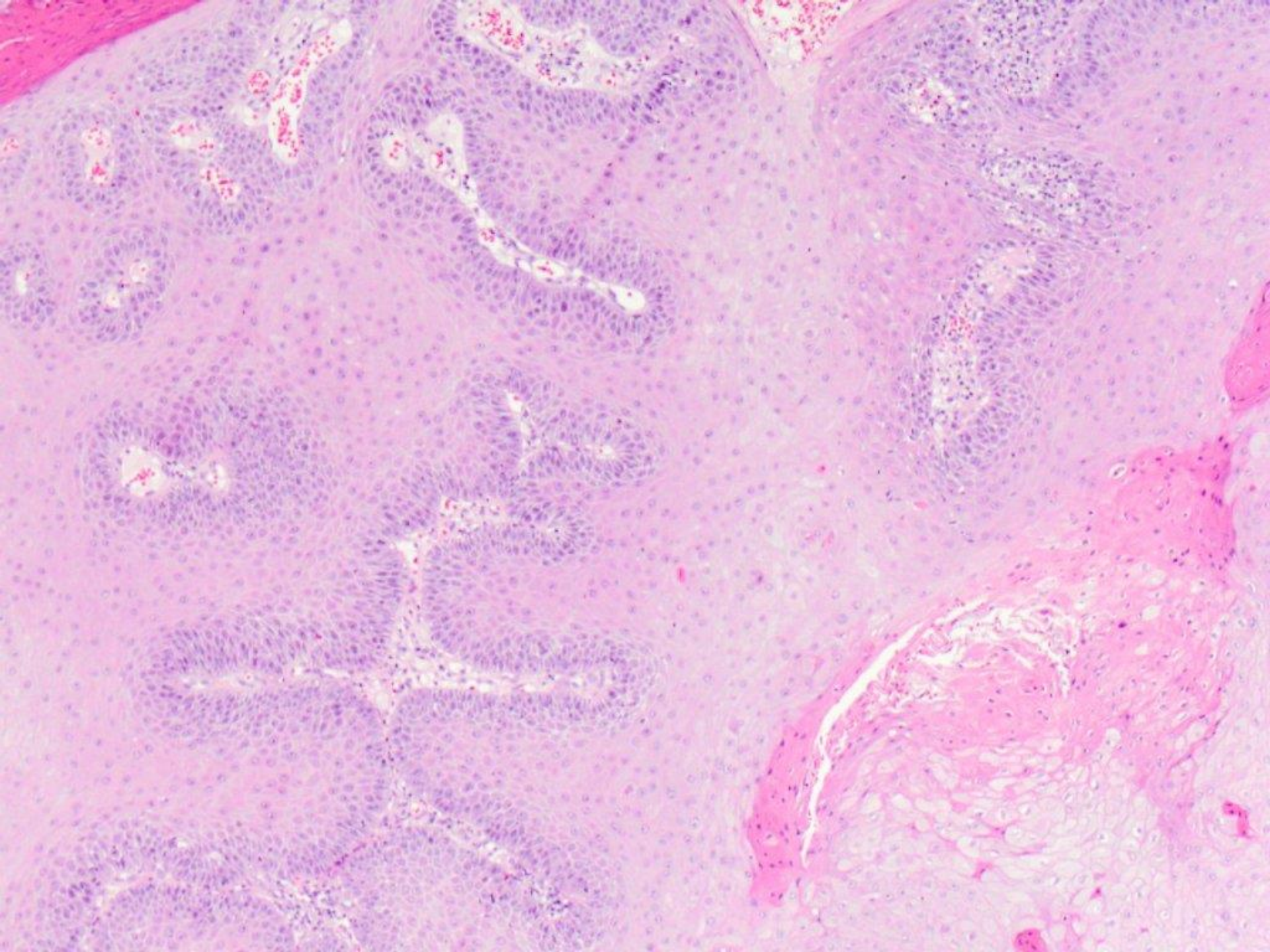




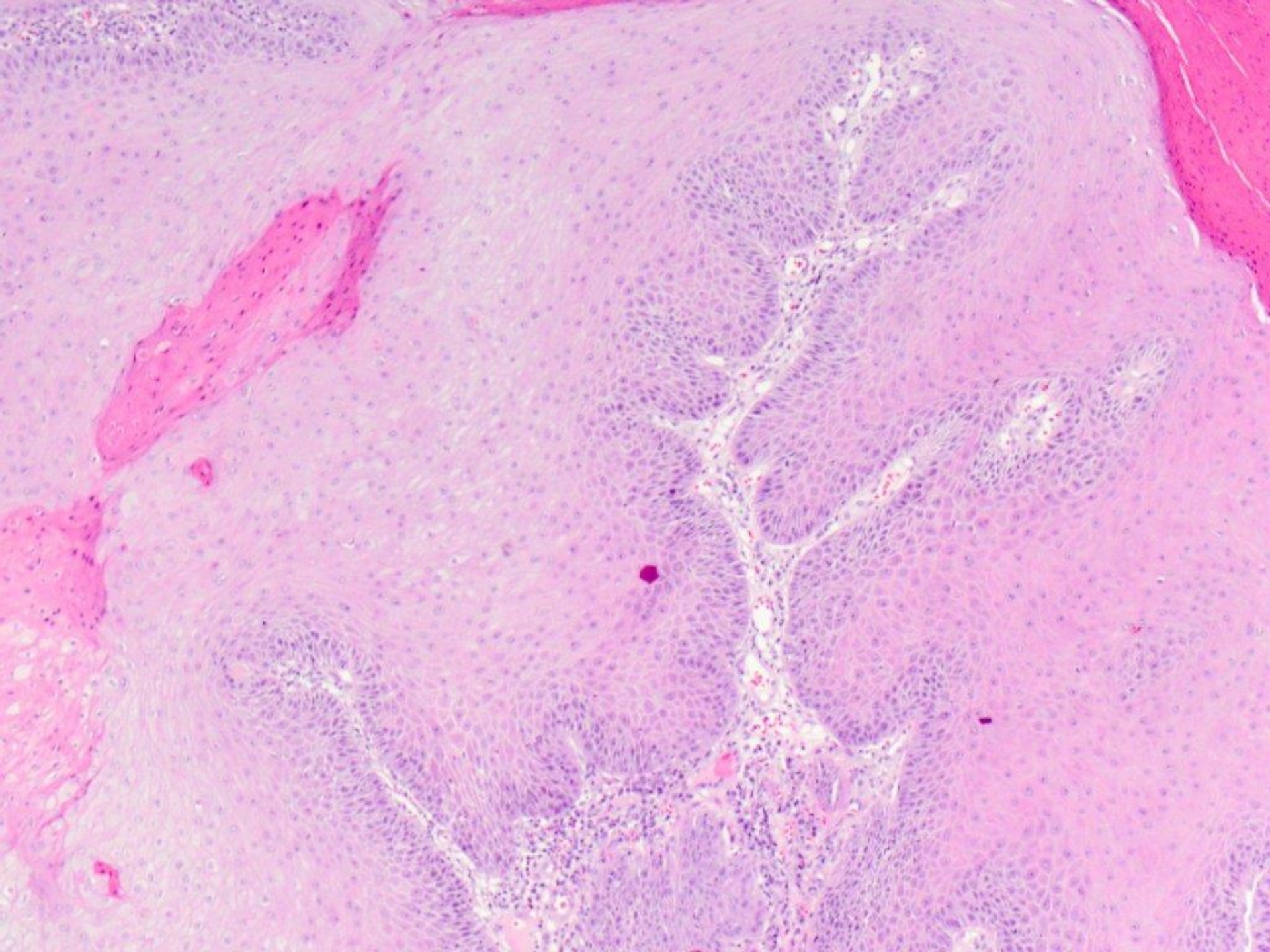




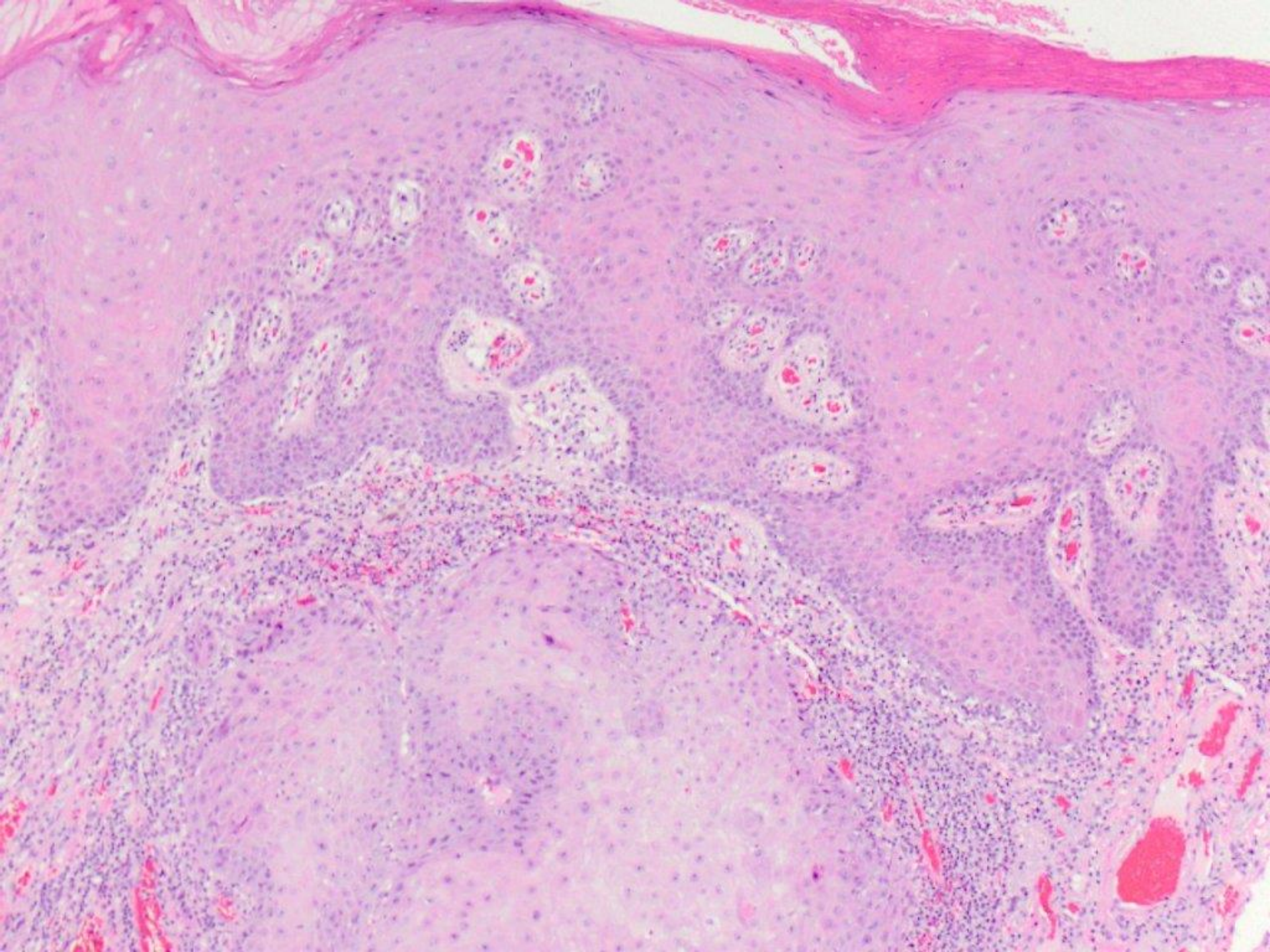




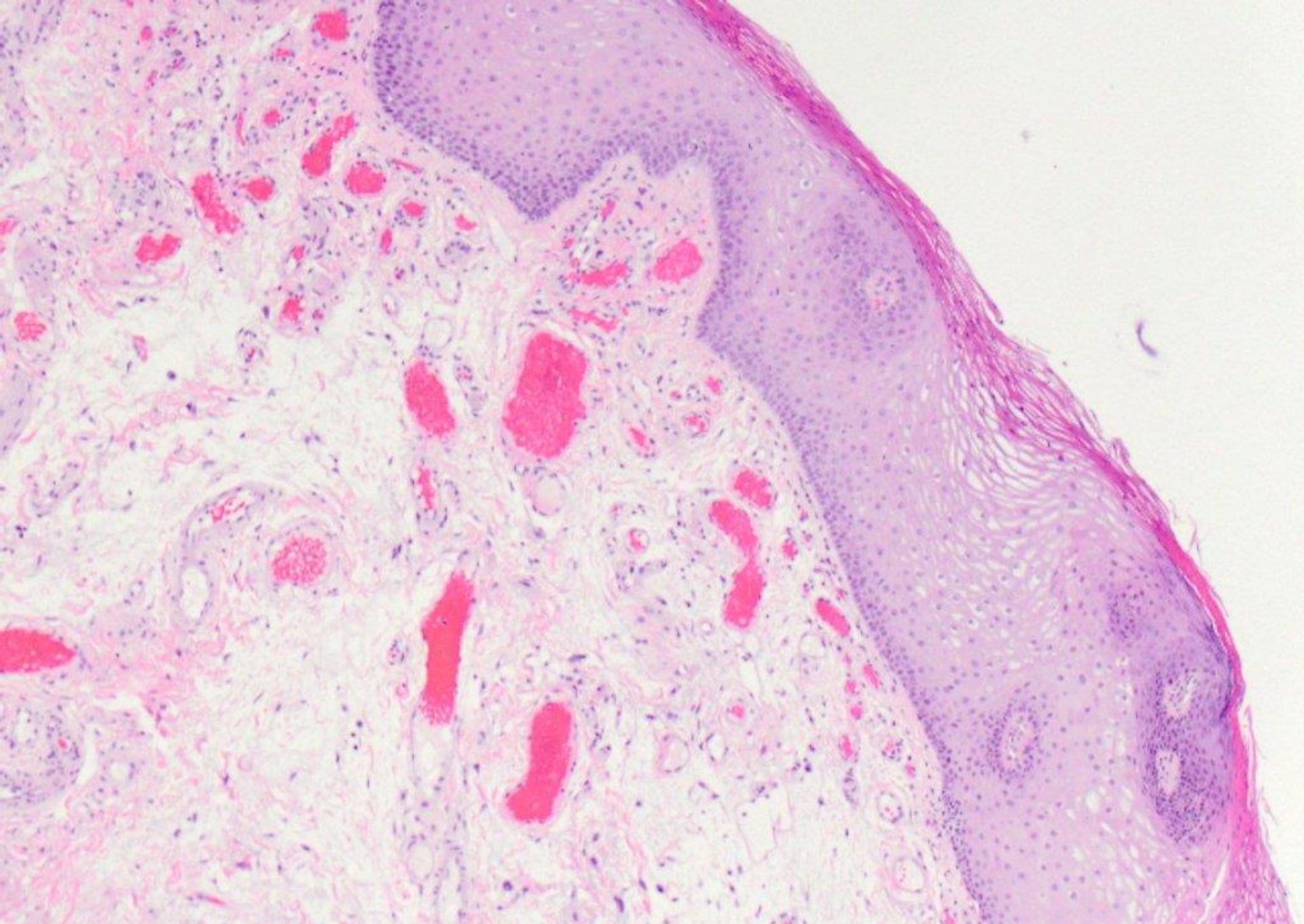












verrucous carcinoma